Journal of Dental and Oral Health

Scient Open Access
Exploring the World of Science

ISSN: 2369-4475

Case Report

A Case of Orthodontic Treatment for a Patient with Occlusal Abnormality Due to Epileptic Seizure

This article was published in the following Scient Open Access Journal:
Journal of Dental and Oral Health
Received August 14, 2017; **Accepted** August 30, 2017; **Published** September 04, 2017

Noboru Demura[1]*, Miho Hasumoto[2] and Taichi Demura[2]
[1]Associate Professor, Orthodontic Division of Oral-facial Surgery, Kanazawa Medical University Affiliciation American Association of Orthodontics (A.A.O.) Japanese Orthodontic Society, Japan
[2]Assistant Professor, Orthodontic division of Oral-facial Surgery, Kanazawa Medical University Affiliciation Japanese Orthodontic Society, Japan

Introduction

Epilepsy is a chronic cerebral disease in which seizures occur repeatedly, being caused by hyperstimulation of intracerebral neurons. Neurons usually deliver weak electrical signals to exchange information; however, when a strong current suddenly flows, unconsciousness and twitching (seizure) of a limb develop. The incidence of epilepsy is 0.5–1%, being widely noted between infancy and senescence. In this study, we orthodontically treated a patient in whom aggravation of malocclusion was induced by an epileptic seizure.

Case

The patient was a female aged 17 years at the first examination, who visited the Department of Dento-stomatology, Kanazawa Medical University Hospital, with a chief complaint of malocclusion after epileptic seizure in July 2009. Regarding the patient's history, she had noticed the aggravation of a headache in 2005 and visited the Department of Pediatrics at our hospital (clinical diagnosis: migraine). Regarding the family history, although no epileptic sufferers were present in her family, her mother frequently suffered from a headache. Regarding the history of the present illness, the patient had a sudden seizure while sleeping at home after returning from a trip by night bus in July 2009, and was transported to our hospital by ambulance. The patient was hospitalized in the Department of Internal Medicine after emergency treatment, and was referred to our department for consultation during hospitalization.

Facial findings

Facial photographs (Figure 1) showed that the frontal appearance was almost symmetrical and, on the facial profile, slight retrusion of the mandible was noted. No facial injury due to epileptic seizure was present.

Intraoral findings

The mandibular bilateral central incisors and left lateral incisor were labiallydisplacement due to subluxation, presenting anterior cross-bite with the maxillary anterior teeth (Figure 2). The degree of mobility of the 3 teeth was M2, without swelling or pain in the area. Furthermore, the maxillary dentition showed slight crowding. The molar relationship was Angle class II malocclusion on the right side, and Angle class III malocclusion on the left side. Overbite was +1.2 mm and overjet was -5.9 mm.

Panoramic and mandibular anterior tooth dental X-ray findings

Panoramic and mandibular anterior tooth dental X-ray photographs (Figure 3) at the first examination showed no fracture of the mandibular anterior teeth or bone fracture. The third molars were present on the supero-inferior bilateral sides. Furthermore, clicking or pain in the temporomandibular joint area or disturbance of mouth opening was absent at the first examination. No discomfort had been noted until the completion of treatment.

Frontal and lateral cephalometric photographs

Lateral cephalometric measurements: N-Me +1 S.D., SNA 80.0°, SNB 77.0°, ANB 3.0°, I.I.A -2 S.D., FMIA -3 S.D. Labial transposition of the mandibular anterior teeth was noted (Figures 4 and 5).

***Corresponding Author:** Noboru Demura, Kanazawa Medical University, 1-1 Daigaku, Kahoku-gun, Uchinada, Ishikawa-Pref, Japan, 920-0235, Tel: 81-76-286-2211(ext.4101) Fax: 81-76-286-2010, Email: ln-demura@kanazawa-med.ac.jp

Figure 1: Facial photographs at the first examination.

Figure 2: Intra-oral photographs at the first examination.

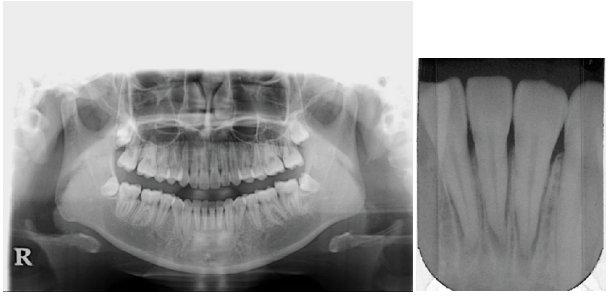

Figure 3: Panoramic and mandibular anterior tooth dental X-ray photographs.

Diagnosis

Labial transposition of the mandibular anterior teeth due to epileptic seizure.

Treatment Guidelines

Arrangement of the labially transpositioned mandibular anterior teeth using a multi-bracket system to achieve favorable maxillo-mandibular dentition

Medical treatment guidelines were the administration of antiepileptic agents and course observation. Tegretol had been administered twice a day (in the morning and evening) for approximately 6 months after the seizure, and Depakene has been administered thereafter. The patient has shown no epileptic seizures, visiting a family doctor for regular medical examinations approximately every 3 months.

Treatment course

The maxillary and mandibular multi-brackets were placed in September 2009, and orthodontic treatment was initiated (Figure 6). During the insertion of the multi-brackets , a rubber mouthpiece was inserted in the maxilla at night to prevent potential harmful effects of an epileptic seizure on the dentition. For lingual reduction of the labially displaced mandibular anterior teeth with mobility, careful tooth movement was performed. As a result, no excessive mobility occurred, and an appropriate mandibular anterior tooth position was achieved. No extraoral anchorage such as headgear was used in combination with the multi-brackets. Although the labial transposition of the mandibular anterior teeth improved after approximately 6 months, because crowding in the maxillary anterior tooth and premolar areas was removed at the same time as the treatment of the mandibular anterior teeth, deep overbite of the maxillo-mandibular anterior tooth area (overbite +4 mm) occurred, showing maxillary protrusion. Therefore, we consulted the patient and her parents regarding the extraction of the premolars after reevaluation; however, because the patient hoped to go to university in a remote area, the patient and her parents did not select tooth extraction, and dynamic treatment for approximately one year and 6 months was completed without extracting teeth in May 2011.

Treatment results

The labial transposition of the mandibular anterior teeth improved, and a favorable occlusal relationship in the anterior tooth and molar areas was achieved. No mobility of the mandibular anterior teeth was present, without discomfort such as cold water pain (Figure 7and 8). shows facial photographs,

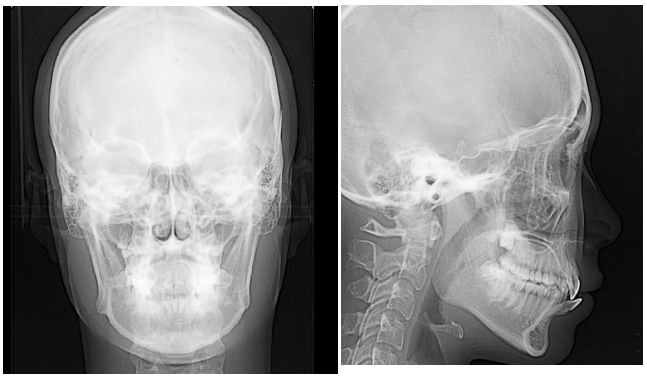

Figure 4: Cephalograms at the first examination.

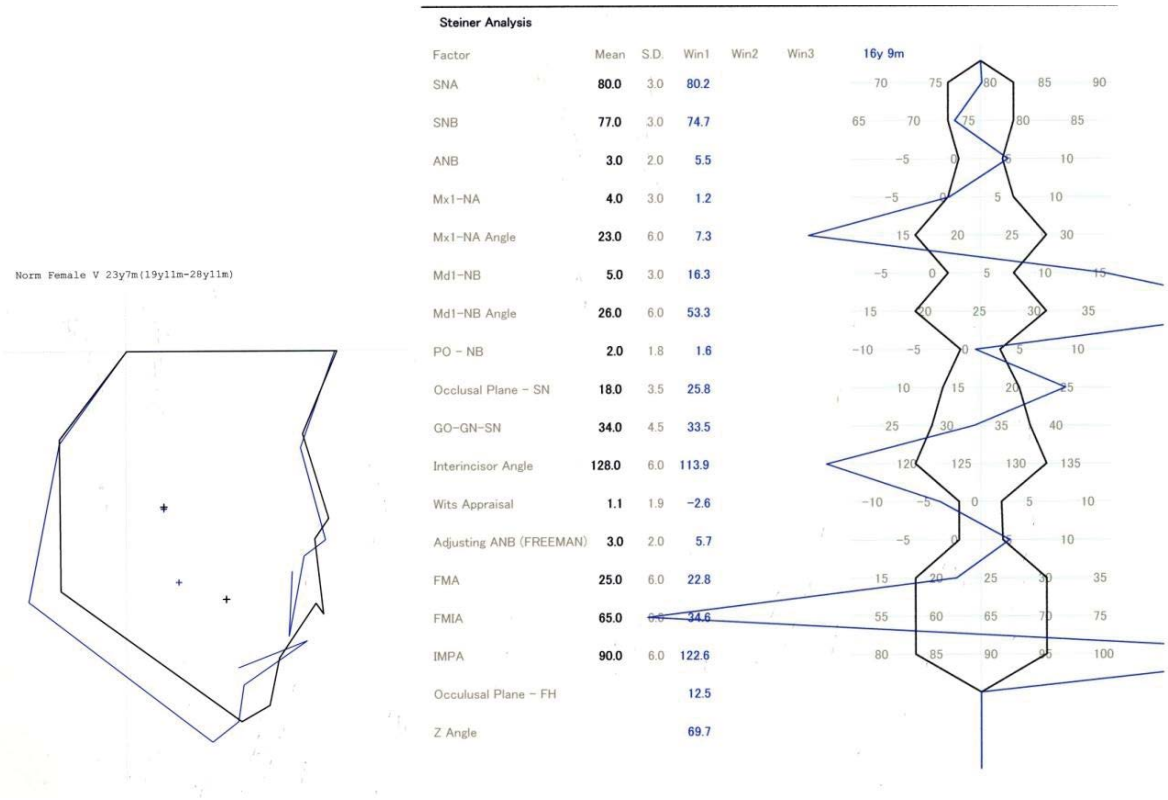

Figure 5: Profilogram at the first examination and analytical results.

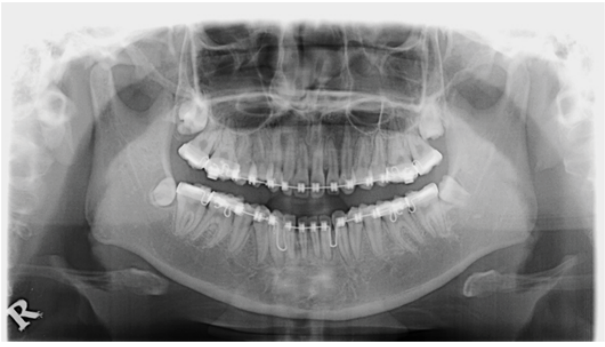

Figure 6: Panoramic X-ray photograph (during treatment).

Figure 7: Intra-oral photographs at the time of the completion of treatment.



Figure 8: Facial photographs at the time of the completion of treatment.

Figure 9 shows cephalographic photographs, and Figure 10 shows a panoramic X-ray at the time of treatment completion. Cephalogram after treatment and overlapping of cephalograms before and after treatment (Figure 11) showed the lingual movement of the mandibular anterior teeth. Furthermore, as a result of the improvement of crowding in the maxillary anterior tooth area, the maxillary anterior teeth showed slight labial inclination. Although retention and course observation have been performed, no relapse of the mandibular anterior teeth has occurred. Furthermore, no epileptic seizure has occurred during the period of dynamic treatment and retention.

Discussion

We treated a patient with labial transposition of the mandibular anterior teeth due to epileptic seizure, and a favorable result was achieved. In this case, epileptic seizure did not occur during the period of dynamic treatment (inserting the multi-bracket system). The use of intermaxillary elastic was possible; however, we did not use headgear.

Epilepsy is a chronic cerebral disease caused by various diseases, and its main characteristic is repetitive seizure (epileptic seizure) due to hyper-discharge in cerebral neurons, with the expression of varied clinical and laboratory findings (WHO, International Classification of Diseases, 10th version). Causes of epilepsy are considered to be cerebral injury or neural abnormalities, and epilepsy is classified into idiopathic (genuine) and symptomatic epilepsies. Idiopathic epilepsy shows no apparent cerebral disorders, and its cause is not identified.

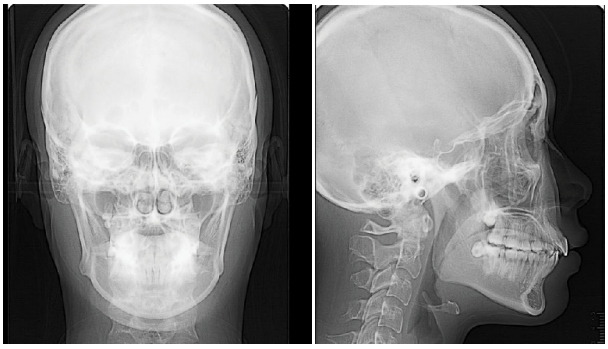

Figure 9: Cephalograms at the time of the completion of treatment

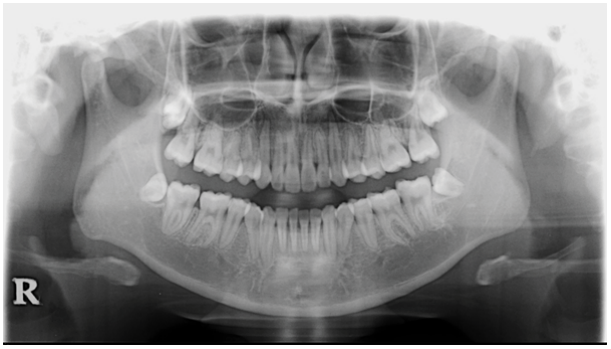

Figure 10: Panoramic X-ray photograph at the time of the completion of treatment

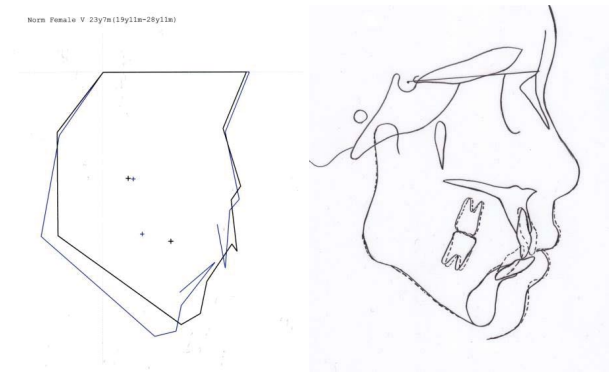

Figure 11: Profilogram after treatment and overlapping of cephalograms from before and after treatment

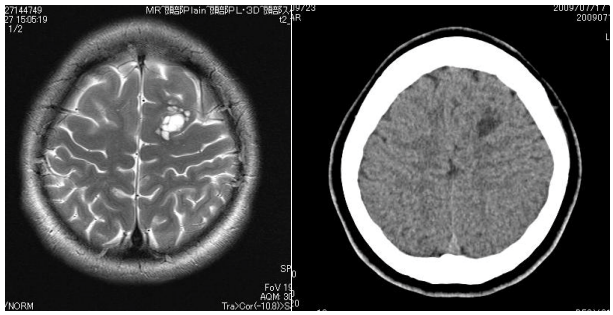

Figure 12: MRI (left) and CT (right) images of the head

Symptomatic epilepsy occurs due to cerebral injury, such as cerebral disorders before and after birth, trauma in the head by traffic accidents, brain tumors, and encephalitis [1]. Figure 12 shows CT and MRI images of the head of the patient. Because a causative area of epilepsy is noted in the right frontal lobe, it was considered to be symptomatic epilepsy. However, because no clear epileptic seizure had occurred, without a need to obtain CT and MRI images of the head, the patient and her parents did not know that she had epilepsy until she was admitted to our hospital for examination.

Regarding the treatment methods of epilepsy, pharmacotherapy using antiepileptic agents is usually the first choice, and surgical treatment is applied in intractable cases in which drug administration is not effective [2]. Commercially available antiepileptic agents are carbamazepine (Tegretol), phenytoin (Aleviatine), and sodium valproate (Depakene) [3,4,5]. Because the incidence of epilepsy is 0.5-1%, being widely noted between infancy and senescence, sufficient attention is necessary when orthodontists initiate treatment for epileptic patients from the first examination. As shown in this case, because some patients and their parents do not notice epilepsy until the first examination, careful treatment is required.

It is important to perform an interview and confirm the past medical history and the present illness of epilepsy at the first examination. Furthermore, when a medical history of epilepsy is noted, it is necessary to ask the attending doctors about the conditions of the disease and medication, for confirmation. It has been reported that 80% of epileptic seizures can be suppressed by appropriate administration.

There have been few reports on orthodontic treatment for epileptic patients [6]. From the experience of treating this case, it is considered that removable appliances, such as headgear (HG), should not be used for orthodontic treatment. Furthermore, when edge-wise appliances are inserted, insertion of rubber mouthpieces is considered to be a favorable method to cope with the occurrence of epileptic seizure, as shown in this study.

When orthodontists perform orthodontic treatment for epileptic patients, it is important to perform a sufficient interview, to ask attending doctors about the present conditions of the disease and medication, and to consider appropriate appliances and methods for orthodontic treatment.

References

1. R. Oothuka: Treatment and diagnosis of epileptic seizure: Japanese journal on developmental disabilities. 2010:32;222-231.
2. K Imon, K Uchimasu, A Okai, et al. Hi risk 30 drugs for nurse -Antiepileptic seizure drug. *Expert Nurse*. 2011;27:134-138.
3. M Ichikawa, E Itoh, T Sato et al. Clinical guide for Antiepileptic seizure drug. *Practical Currently*. 2011:21:403-408.
4. S Tobimatu. New standards- Epileptic seizure treatment Clinical Neuro science 2011:29;20-24.
5. K. Matsubara. Anti epileptic seizure drug. *Brain Nursing*. 2010;26:1112-1117.
6. H. Kobayashi, M. Sakuta. Orthodontic treatment in epileptic seizure patient. *Dental Diamond*. 1992;17:112-114.