

## A New Surgical Technique in Congenital Cataract with Femtosecond Laser

This article was published in the following Scient Open Access Journal:

Journal of Ophthalmology & Visual Neurosciences

Received February 24, 2016; Accepted March 03, 2016; Published March 09, 2016

**Bordin P\* and Vizzari G**

Department of Ophthalmology, Hospital of Legnago,  
Verona, Italy

### Purpose

The aim of this study is to describe a new technique for performing a safer surgery in infants with congenital cataract by using a femtosecond laser (FLACS) for anterior and posterior capsulotomy [1,2].

### Case Report

A 2-year-old male presented with bilateral polar cataract visualized on slit-lamp examination. His Best-Corrected Visual Acuity (BCVA) was 20/200 in OD and 20/100 in OS. The keratometry (SRK-T formula) was obtained with IOL Master (Carl Zeiss AG, Feldbach, Switzerland) and the axial length with Ultrasound biomicroscopy. He underwent bilateral FLACS by VICTUS (Technolas Bausch & Lomb, Munich, Germany), followed by implantation of a trifocal intraocular lens (PhysIOL POD F) [3]. The antibiotic topic therapy was started the day before surgery with netilmicin 4 times daily until 15 days after the surgery. The topical FANS was added for 30 days after surgery. The child was hospitalized the day of surgery and he was given cefuroxime as systemic antibiotic prophylaxis. The antibiotic i.v. (2.5 mg/kg) was performed three times within 24 hours only the day of surgery. The general anaesthesia was done and soft docking was performed by using sterile patient interface and sterile BSS (Figure 1). The patient lied on a unique rotating table in order to use the FLACS and the phacoemulsification platform in the same operating room, so as to avoid the risk of infections due to multiple transfers [4]. The anterior capsulotomy was done by femtolaser (Figure 2) [5]. The operating table had been moved under the microscope and clear cornea cuts were performed at 2.2 mm and 1 mm to open the anterior chamber, a cohesive viscoelastic was injected before removing the anterior capsula disk and the lens (Figure 3). After aspiration of the cataract a capsular tension ring was implanted into the bag to avoid the future bag phimosis (Figure 4). The viscoelastic was removed from the anterior chamber and a hole was created in the center of posterior capsule by using a 27 G needle (Figure 5). The cohesive viscoelastic was injected through the gap between the posterior capsula and the hyaloids (Figure 6). In this way it was

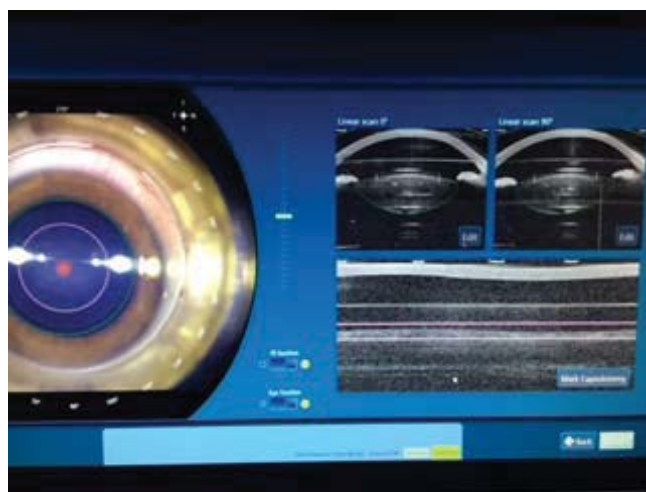


Figure 1: First docking

\*Corresponding author: Dr. Bordin P, Department of Ophthalmology, Hospital of Legnago, Verona, Italy, Email: paolo.bordin@aulsslegnago.it

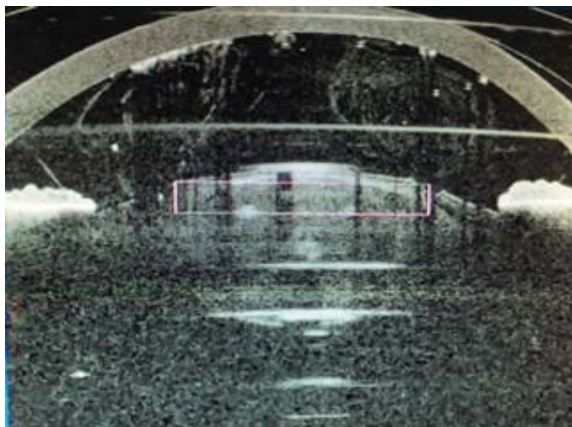


Figure 2. OCT real time, anterior capsulotomy

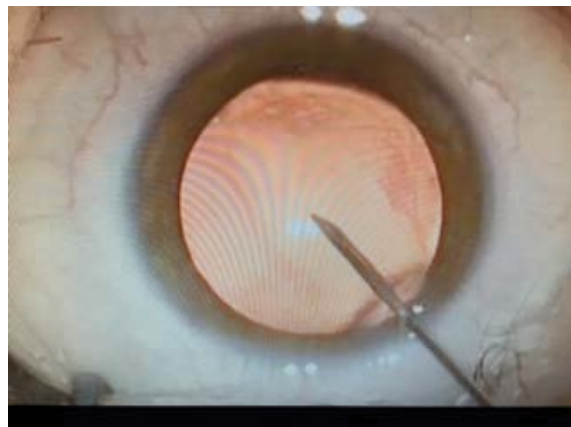


Figure 5: Hole in posterior capsule

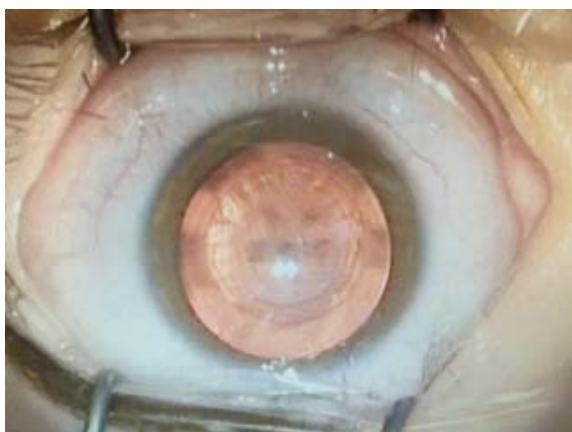

Figure 3: Anterior capsulotomy

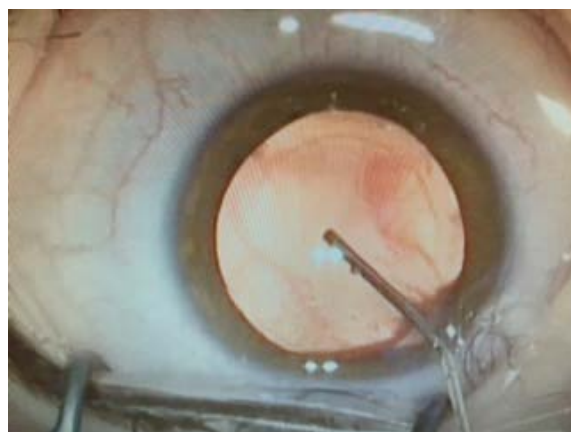


Figure 6: Viscoelastic injection behind the posterior capsule

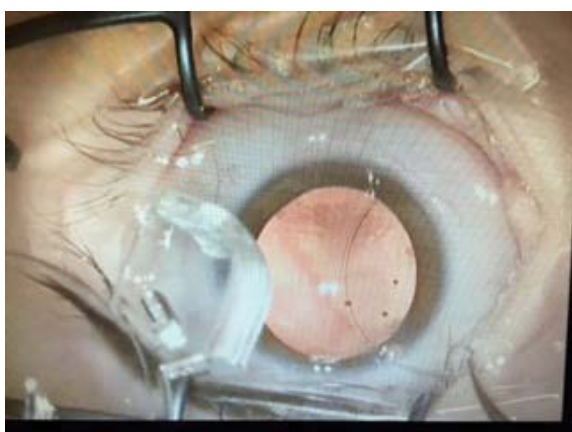

Figure 4: Implant of capsular tension ring

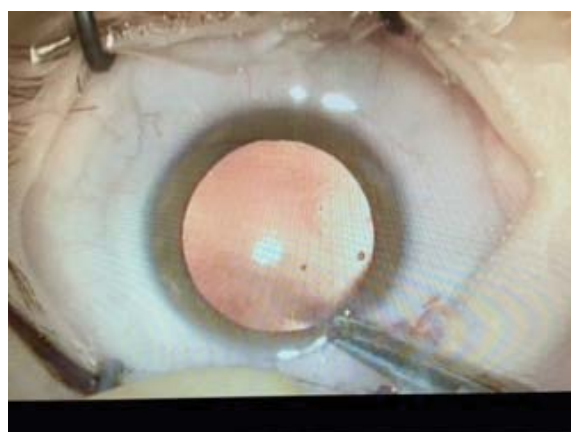

Figure 7: Closure of corneal wound

possible to move the posterior capsule forward and to make it convex as the anterior one. After the closure of the 2.2 mm. corneal wound by using a 10-0 Nylon suture (Figure 7), the operating table was rotated under the femtolaser and a sterile patient interface and a sterile BSS were applied on the eye

of the patient. A new soft docking was performed (Figure 8). With the real time-integrated optical coherence tomography (OCT) it was possible to see the posterior capsule pushed up by the viscoelastic, allowing a centered posterior capsulotomy of 4.5 mm. within the anterior capsulotomy (Figures 9 and

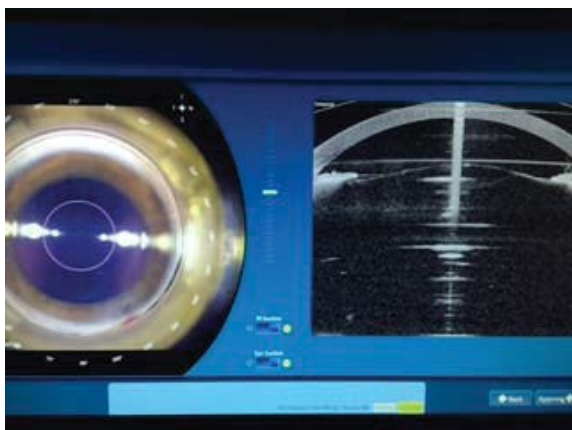


Figure 8: Second docking

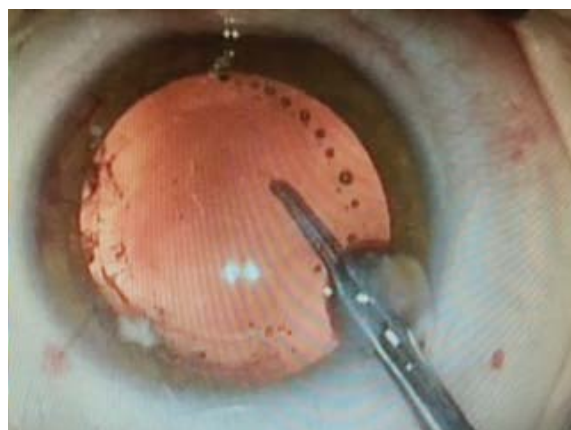


Figure 11: Removal of posterior capsule




Figure 9: OCT real time, posterior capsule is convex

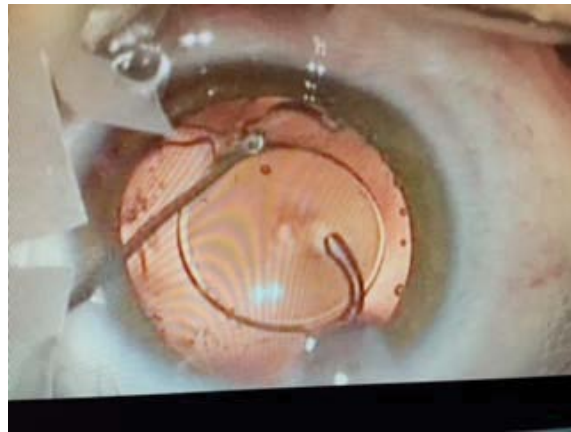

Figure 12: Lens implant



Figure 10: OCT real time, posterior capsulotomy and centered

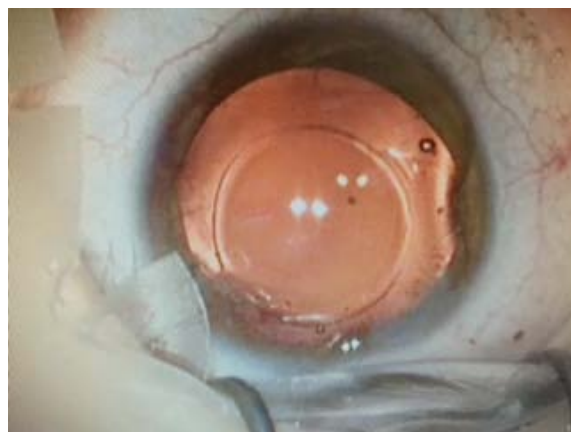

Figure 13: Final results

10). The operating table was moved under the microscope, the wound was reopened and the posterior capsule disk was removed without capsule tears (Figure 11). It was followed by a mechanical anterior vitrectomy and the trifocal IOL was implanted in the bag of both eyes (Figures 12 and 13).

## Results

The child was followed up on day 1, day 5, at 2 weeks, 4 weeks and 8 weeks. At each follow-up visit, complete ocular examinations including slit-lamp and orthoptic examination of both eyes were performed. The corneas were clear and the

intraocular pressure (IOP), recorded by Perkins applanation tonometer, was 15 mmHg in OD and 16 mmHg in OS at every visit. At 4 weeks the BCVA was 20/30 and in OU. Anterior and posterior capsulotomies were complete and uniform, without tears or tags. The IOL was centered in the capsular bag.

## Conclusion

It's the first time that this technique has been performed. The femtolasar capsulotomy is safer than manual one because it is possible to obtain desired size of anterior and posterior capsulotomies. It enables surgical standardization. It can enhance quality and safety of pediatric cataract surgery without tear or loss of capsule during surgery with big problems for the IOL placement. By using the viscoelastic to push up the posterior capsule you can obtain the same shape during the cut of both anterior and posterior capsules. By using femtolasar with real time OCT it is possible to visualize the surface of both capsules

during the surgery. By using femtolasar with mobile operating table it is possible to avoid multiple transfers of the patient. This makes the surgery an extremely safe procedure.

## References

1. Dick HB, Schultz T. Femtosecond laser-assisted cataract surgery in infants. *J Cataract Refract Surg.* 2013; 39(5):665-668.
2. Lloyd IC, Ashworth J, Biswas S, Abadi RV. Advances in the management of congenital and infantile cataract. *Eye* 2007; 21:1301-1309.
3. Dick HB, Schelenz D, Schultz T. Femtosecond laser-assisted pediatric cataract surgery: Bochum formula. *J Cataract Refract Surg.* 2015; 41(4):821-826.
4. Anagha Medsinghe, Ken K Nischal. Pediatric cataract: challenges and future directions. *Clin Ophthalmol.* 2015; 9:77-90.
5. Trikha S, Turnbull AM, Morris RJ, Anderson DF, Hossain P. The journey to femtosecond laser-assisted cataract surgery: new beginnings or a false dawn? *Eye (Lond).* 2013; 27(4): 461-473.