

Congenital Diaphragmatic Hernia With Intrathoracic Kidney: An Unusual Presentation

This article was published in the following Scient Open Access Journal:

Journal of General and Emergency Medicine

Received November 15, 2016; Accepted November 23, 2016; Published November 30, 2016

Mahdi Ben Dhaou¹, Mohammed Zouari^{1*},
Salma Ben Ameer², Hayet Zitoumi¹, Mihamed

Jalloul¹, Monjia Hachida² and Riadh Mhiti¹

¹Department of Pediatric Surgery, Hedi Chaker
Hospital, 3029 Sfax, Tunisia, North Africa

²Department of Pediatrics, Hedi Chaker Hospital,
3029 Sfax, Tunisia, North Africa

Abstract

Intrathoracic renal ectopia is the rarest developmental anomaly among all ectopic kidneys with a prevalence of less than 0.01%. Intrathoracic renal ectopia associated with a congenital diaphragmatic hernia represents an extremely rare congenital malformation. In this paper we report a 2-year-old female infant with late-presenting congenital diaphragmatic hernia associated with a right-sided intrathoracic ectopic kidney. After recurrent episodes of dyspnea, a chest x-ray showed air-filled loops of the bowel in the right hemithorax and a paucity of gas in the abdomen. Computed tomography scan demonstrated right-sided Bochdalek hernia with the right kidney within the thorax. Surgery was performed via a thoracoscopic approach. The postoperative course was uneventful. Clinicians should maintain a high index of suspicion for this rare malformation even beyond the neonatal period to avoid delay in diagnosis and inappropriate management.

Keywords: Intrathoracic renal ectopia, Kidney, Congenital diaphragmatic hernia, Children

Introduction

Intrathoracic renal ectopia (IRE) is the rarest developmental anomaly among all ectopic kidneys with a prevalence of less than 0.01% [1]. The incidence of IRE as a result of congenital diaphragmatic hernia was reported to be less than 0.25% [1]. Males are affected preponderantly and the left side is more commonly involved [2,3]. Right-sided thoracic kidney is much less common due to the location of the liver. We report on a case of late-diagnosed intrathoracic kidney associated to a right-sided congenital diaphragmatic hernia.

Case Report

A 2-year-old female child was admitted to the department of pediatrics with the complaints of recurrent episodes of dyspnea, but without any history of respiratory infection. She was born at full-term by vaginal delivery with a birth weight of 3200 g. The prenatal ultrasound showed no pathological result. On physical examination, she was afebrile, his respiratory rate was 44/min and SPO₂ 98%. A chest radiograph (Figure 1) showed air-filled loops of the bowel in the right hemithorax and a paucity of gas in the abdomen; the right diaphragm was not discernable. Computed tomography (CT) of the chest (Figure 2) demonstrated the presence of an ectopic reniform structure with bowel loops in the intrathoracic location on the right side. The liver and the left kidney were in their normal positions. Thoracoscopy revealed a posterolateral defect in the diaphragm with a thin membrane. The right kidney could easily be identified in the hernia sac. A pneumothorax was created using the CO₂ insufflator at a pressure of 6 mmHg. The hernial contents were reduced and the diaphragmatic defect was closed by primary repair. The right kidney was mobilised without difficulty in a near to normal site. Postoperative recovery was uneventful. Abdominal ultrasonography with renal Doppler study carried out one month after surgery showed persistent correct position of the right kidney with normal vascularity and normal renal vessels. The child has been followed up now for 2 years without complaints and no renal pathology was detected with ultrasonographic studies.

*Corresponding Author: Mohamed Zouari, Hedi Chaker Hospital, 3029 Sfax, Tunisia, Tel: 0021697459586, Email: zouarimohamed.1982@yahoo.fr

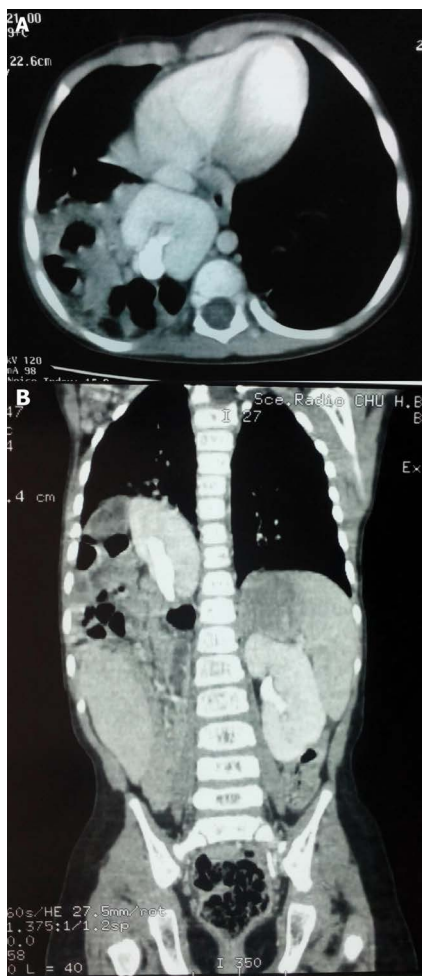


Figure 1: (A) Contrast-enhanced axial computed tomography (CT) scan demonstrating the presence of an ectopic reniform structure with bowel loops in the intrathoracic location on the right side. (B) Contrast-enhanced coronal CT scan demonstrating the presence of an ectopic reniform structure with bowel loops in the intrathoracic location on the right side.

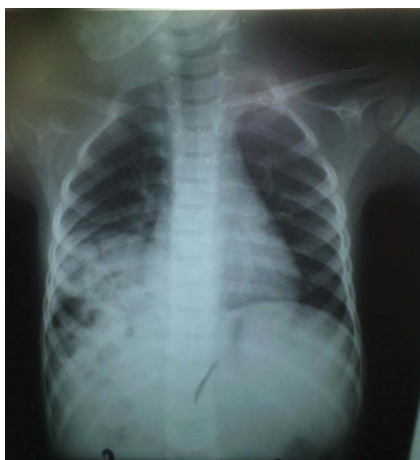

Figure 2: Chest radiograph showing air-filled loops of the bowel in the right hemithorax and a paucity of gas in the abdomen. The right diaphragm is not discernible.

Discussion

Intrathoracic renal ectopia represents a partial or complete renal protrusion above the level of the diaphragm into the posterior mediastinum. It is a rare form of renal ectopia and, in the autopsies of 15919 children, 22 cases of renal ectopia were detected, with only one case of IRE [4]. This anomaly is rarely bilateral, involves the left kidney more commonly (62%) than the right side (38%) and affects males three times more frequently than females [5]. The low frequency of right thoracic ectopia is explained by the early fusion of the pleura-peritoneal channel on the right side and by the presence of the liver as a physical barrier [6]. Embryologically, the kidneys ascend from the pelvis during the fifth week of gestation. They reach their adult location by the eighth week of gestation. At approximately the same gestational age, the pleuroperitoneal membrane forms the diaphragm leaflets [1,6]. Various mechanisms have been thought to be responsible for intrathoracic kidneys such as accelerated ascent of the kidney, delayed closure or maldevelopment of the pleuroperitoneal membrane, effect of the developing liver and adrenal glands, and the persistence of the nephrogenic cord [5,7]. Thoracic kidneys are classified into four groups: thoracic renal ectopia with 1) closed diaphragm, 2) eventration of the diaphragm, 3) diaphragmatic hernia, which is subdivided into congenital diaphragmatic defects and acquired hernia, such as Bochdalek hernia and 4) traumatic rupture of the diaphragm [8,9]. Anatomical features have been associated with intrathoracic kidneys including rotational irregularities with the hilum facing inferiorly, distorted shape, elongated urethra, high origin of renal vessels, and medial deviation of the lower renal pole [10,11]. However, IRE is usually associated with normal renal function with no dysplastic parenchymal changes unlike pelvic renal ectopia, which sometimes undergoes obstruction, develops calculi or gets infected [12]. Most patients with intrathoracic ectopic kidney are diagnosed incidentally and have no specific symptoms referable to the misplaced kidney [13]. For the diagnosis of thoracic kidney, chest radiography can be useful. Ultrasonography, CT scan, magnetic resonance imaging and other techniques are used complementarily for differential diagnoses [6,14-16]. Cases of intrathoracic ectopic kidney with right congenital diaphragmatic hernia are extremely rare [13]. Congenital diaphragmatic hernia (CDH) is a rare condition seen in 2/5000 live births [17]. Most cases of congenital diaphragmatic hernia are diagnosed within the first few hours of life, with 5-25% of diaphragmatic hernias appearing beyond the neonatal period [18]. Late-presenting CDH may pose significant diagnostic problems because of non-specific clinical signs, and result in delayed diagnosis [19-21]. For children with CDH and IRE, surgical treatment, including hernia repair and nephropexy, is indicated. Late-presenting CDH shows a better prognosis than early-presenting CDH [21]. This is not surprising considering that children with late-presenting CDH had already survived for some time with the condition, suggesting that the degree of herniation was not life-threatening.

Conclusion

Intrathoracic renal ectopia with Bochdalek's hernia is an extremely rare association. Clinicians should maintain a high index of suspicion for this congenital anomaly even beyond the neonatal period to avoid delay in diagnosis and inappropriate management.

Conflict of Interest

None declared

Source of Support

Nil

References

1. Donat SM, Donat PE. Intrathoracic kidney: a case report with a review of the literature. *J Urol*. 1988;140(1):131-133.
2. Fiaschetti V, Velari L, Gaspari E, Mastrangeli R, Simonetti G. Adult intrathoracic kidney: A case report of bochdalek hernia. *Case Report Med*. 2010;2010.
3. Motiani PD, Gupta PK, Aseri KC, et al. Bochdalek hernia on the right side in an adult - case report and review. *Lung India*. 1991;(2):63-65.
4. Campbell MF. Renal ectopy. *J Urol*. 1930;24:187-90.
5. Sozubir S, Demir H, Ekingen G, Guvenc BH. Ectopic thoracic kidney in a child with congenital diaphragmatic hernia. *Eur J Pediatr Surg*. 2005;15(3):206-209.
6. Maduekwe E, Weinberg B, Samaan B, Ergeba Sheferaw, Patcharapong Suntharos. Right thoracic ectopic kidney in a child with breathing difficulties-sonographic diagnosis. *J ClinUltrasound*. 2011;39(2):108-110.
7. Aydin HI, Sarici SU, Alpay F, Gokçay E. Thoracic ectopic kidney in a child: a case report. *Turk J Pediatr*. 2000;42(3):253-255.
8. N'Guessen G, Stephens FD, Pick J. Congenital superior ectopic (thoracic) kidney. *Urology*. 1984;24(3):219.
9. Pfister-Goedeke L, Brunier E. Intrathoracic kidney in childhood with special reference to secondary renal transport in Bochdalek's hernia. *Helv Paediatr Acta*. 1979;34:345-357.
10. Panda B, Rosenberg V, Cornfeld D, Daniel cornfeld. Prenatal diagnosis of ectopic intrathoracic kidney in a fetus with a left diaphragmatic hernia. *J Clin Ultrasound*. 2009;37:47-49.
11. Ramos AJ, Slovis TL, Reed JO. Intrathoracic kidney. *Urology*. 1979;13:14-19.
12. Murphy JJ, Altit G, Zerhouni S. The intrathoracic kidney: Should we fix it? *J Pediatr Surg*. 2012;47:970-973.
13. Jeong BD, Ahn SH, Song JW, et al. Impaction of an intrathoracic kidney acted as a shield against herniation of the abdominal viscera in a case of right congenital diaphragmatic hernia. *Obstet Gynecol Sci*. 2016;59(1):58-61.
14. Aydin HI, Sanci SU, Alpay F, et al. Thoracic ectopic kidney in a child: a case report. *Turk J Pediatr*. 2000;42:253-255.
15. Hithaishi C, Padmanabhan S, Kumar BS, et al. Ectopic thoracic kidney - a case report. *Indian J Nephrol*. 2003;13:79-80.
16. SinghH, SharmaP, NazarAH, et al. Ectopic thoracic kidney: Evaluation using 99mTc dimercaptosuccinic acid SPECT-CT. *Clin Nucl Med*. 2012;37:e170-172.
17. BalaylaJ, AbenheimHA. Incidence, predictors and outcomes of congenital diaphragmatic hernia: a population-based study of 32 million births in the United States. *J Matern Fetal Neonatal Med*. 2014;27(14):1438-1444.
18. Mishalany H, Gordo J. Congenital diaphragmatic hernia in monozygotic twins. *J Pediatr Surg*. 1986;21:372-374.
19. Muzzafar S, Swischuk LE, Jadhav SP. Radiographic findings in late-presenting congenital diaphragmatic hernia: helpful imaging findings. *PediatrRadiol*. 2012;42:337-342.
20. De Castro FJ, Schumacher H. Asymptomatic thoracic kidney. *Clin Ped*. 1989;8(5):279-280.
21. Chang SW, Lee HC, Yeung CY, et al. A twenty-year review of early and late-presenting congenital Bochdalek diaphragmatic hernia: are they different clinical spectra? *Pediatr Neonatol*. 2010;51(1):26-30.