

## The Effects of Computer-Aided Anteroposterior Forehead Movement on Ratings of Facial Attractiveness

This article was published in the following Scient Open Access Journal:

Journal of Dental and Oral Health

Received April 18, 2017; Accepted May 08, 2017; Published May 15, 2017

Heidi S. Ellis<sup>1</sup>, Farid Hamidzadeh<sup>1</sup>, Sennay M. Stefanos<sup>2</sup>, Minoo Rouhanian<sup>3</sup>, Jayson H. Huber<sup>4</sup>, Marc E. Arena<sup>5</sup> and Ling Ye<sup>6\*</sup>

<sup>1</sup>Department of Comprehensive Dentistry, Naval Postgraduate Dental School, Navy Medicine Professional Development Center, 8955 Wood Road, Bethesda, MD 20889-5628, USA

<sup>2</sup>Department of Orthodontics, Naval Postgraduate Dental School, Navy Medicine Professional Development Center, 8955 Wood Road, Bethesda, MD 20889-5628, USA

<sup>3</sup>Department of Research Programs, Walter Reed National Military Medical Center, 8955 Wood Road, Bethesda, MD 20889-5628, USA

<sup>4</sup>Department of Comprehensive Dentistry, Naval Postgraduate Dental School, Navy Medicine Professional Development Center, 8955 Wood Road, Bethesda, MD 20889-5628, USA

<sup>5</sup>Department of Comprehensive Dentistry, Naval Postgraduate Dental School, Navy Medicine Professional Development Center, 8955 Wood Road, Bethesda, MD 20889-5628, USA

<sup>6</sup>Department of Research, Naval Postgraduate Dental School, Navy Medicine Professional Development Center, 8955 Wood Road, Bethesda, MD 20889-5628, USA

### Abstract

**Objective:** L. F. Andrews proposed to use forehead as a reference to position maxillary incisors since it is external and does not move during the course of treatment, and also suggested not to place maxillary incisors anterior to the soft tissue glabella. The goal of this study is to determine whether changes in patient's forehead will affect evaluators' subjective ratings of facial attractiveness, and if anterior placement of maxillary incisors will adversely affect attractiveness.

**Materials and Methods:** Smiling profile photographs of one female Caucasian, one female African American, and one female Asian model were captured. The photographs were then digitally manipulated at the soft tissue glabella to simulate forward movement by 2, 4, and 6 mm and backward by 2 mm. Twenty general dentists and twenty laypersons then scored the attractiveness of the photographs using a 0-100 mm visual analogue scale. Friedman's test and Wilcoxon signed rank test were used to analyse the standardized Z-scores for statistical significance between varying anteroposterior positions of the glabella.

**Results:** For all three models, the original photo with maxillary incisors anterior to the soft tissue glabella was the most attractive, and the most extreme change of 6 mm with maxillary incisors placed closer to soft tissue glabella was the least attractive.

**Conclusion:** The study suggests that changes of anteroposterior position of the glabella affect the appreciation of facial attractiveness. Our results do not support the proposal to avoid placing the maxillary incisors anterior to the soft tissue glabella.

### Introduction

Successful outcomes in treatment planning involve three basic steps: proper diagnosis, a thorough treatment plan, and flawless execution of the chosen treatment. If facial esthetic outcomes, are not taken into account during this initial treatment planning phase, even with the best of treatment plans the final results may be less than optimal due to facial esthetic desires of the patient [1]. As a result, facial esthetics should have a higher priority in the treatment planning process, and should be evaluated early in the treatment planning process [2].

In severe cases of malocclusion, orthodontists and oral surgeons routinely plan cases in which they move one or both jaws. In preparation for these complicated surgical cases, there is not a universally accepted method for determining the anteroposterior position of the jaws. The following are a few references that have been proposed in the field of orthodontics. Tweed described the use of Frankfort-Mandibular Incisor Angle as a diagnostic reference utilizing lateral cephalometric tracing [3]. Ricketts defined his reference as the esthetic plane, a line from the nose to the chin [4]. McNamara outlined a step-by-step procedure of cephalometric evaluation of hard tissue landmarks for treatment planning of his orthodontic cases [5]. Holdaway described the use of soft tissue cephalometric analysis in orthodontic treatment planning [6,7]. Arnett and colleagues proposed the true vertical line, which uses subnasale, as a reference in their cephalometric analysis for diagnosis and treatment planning [8].

Andrews rendered each of these landmarks as unpredictable [9,10], because they are either internal and do not represent the external soft tissue, or on areas that are still growing such as the nose [11,12], or they are likely to move unpredictably after treatment [13]. Dr. Andrews, therefore, proposed to use the forehead as a stable landmark to evaluate the anteroposterior relationship [9]. In the 2008 study, Andrews found that in

\*Corresponding Author: Dr. Ling Ye, Naval Postgraduate Dental School, Navy Medicine Professional Development Center, 8955 Wood Road, Bethesda, MD 20889-5628, USA, Email: [ling.ye.mil@mail.mil](mailto:ling.ye.mil@mail.mil)

94 adult white females with good facial harmony, 87 (93%) had the maxillary central incisors positioned anterior to the forehead facial axis (FFA) point (midpoint between trichion/superion and glabella) of the forehead and posterior to the soft tissue glabella [10], and advised never to place the maxillary incisors anterior to the soft tissue glabella [9]. The rationales for this philosophy are that the soft tissue forehead is an external part of the face rather than an internal structure, there is a critical relationship between the maxillary incisors and the forehead, and that attractive faces share a harmony between FFA point and glabella regardless of ethnicity, gender, or age [14]. A recent similar study seemed to corroborate this philosophy, and found that in a group of 101 white male adults with good facial harmony, 91% had maxillary incisors placed between FFA point and glabella [15].

Schlosser, et al. and Cao, et al. manipulated photographs from a Caucasian female and a Chinese female, respectively [16,17]. Both studies found that images generated with maxillary incisors placed in most retrusive position were significantly less desirable than those with maxillary incisors in protrusive position. However, these two studies only simulated the movement of maxillary section including teeth and lip, without any movement of mandibular section, which may cause interference with the judgement of attractiveness. In addition, all the simulations positioned maxillary incisors posterior to the soft tissue glabella even for images with the most advancement. In this study, we sought to explore if soft tissue glabella can serve as a useful landmark and if teeth placed in front of the glabella would be perceived as unattractive for dental professionals and laypersons. The purpose of this study is to determine if changes in the anteroposterior position of a patient's soft tissue glabella affect evaluators' subjective ratings of facial attractiveness for three Caucasian, African American, and Asian models. The null hypothesis is that there will be no difference in the attractiveness after the position of the forehead has changed for the three models.

## Materials and Methods

### Models

The study protocol was submitted to the Walter Reed National Military Medical Center (WRNMMC), and was determined to be "EXEMPT FROM IRB REVIEW" according to federal regulations in category 32 CFR 219.101(b)(2), in compliance with all applicable Federal regulations governing the protection of human subjects. Three volunteer female models, 18 years or older, were selected from orthodontic patient evaluations at Naval Postgraduate Dental School (NPDS), Bethesda, MD. The models represented three different races (Caucasian, African American, and Asian). The models had nasolabial angle within the normal range as described by Fitzgerald, et al. [18]. Exclusion criteria included major skeletal deformities, or in active orthodontic treatment. Each model signed the NPDS release form giving their permission to use their photos.

Right lateral profile photographs were taken by the same photographer with a high definition digital single-lens reflex camera under previously described conditions [16]. The first image was taken in repose and was used to ensure that the patient fell within the inclusion criteria for the study. The second image, a smiling profile photograph, was captured with a 100-mm ruler fixed in front of the model's nose to calibrate for magnification

and a hanging plumb to assist in paralleling the model's head position.

### Image Alteration

The model's smiling profile photograph was altered with Adobe Photoshop CS6 (Adobe systems, McLean, VA). Four altered images were created by moving the soft tissue glabella forward in a horizontal plane by 2 mm, 4 mm, and 6 mm, and backward in a horizontal plane by 2 mm (Figure 1). The alterations were conducted by an information technology (IT) specialist at NPDS with experience using the photo editing software. The ruler and the plumb were removed from the altered photos to eliminate distractions.

The original and altered photos from the Caucasian, African American, and Asian models are shown in Figure 1. In the original photos for all three models, their maxillary incisors are naturally positioned in front of the soft tissue glabella. With forward movement of soft tissue glabella, the maxillary incisors gradually move closer to the vertical line through glabella. For the 6mm photos in Caucasian and Asian models, maxillary incisors are positioned behind the soft tissue glabella.

The original and four altered images of each model were printed on 8.5" x 11" photo paper, labelled 1 through 15, and placed in a binder for evaluation. The photos were randomized for each of the models, and grouped together in the binder adopted from Kokich, et al. [19].

### Judges/Evaluators

Two groups of judges, twenty general dentists and twenty laypersons, were randomly selected to evaluate the profile photographs. The sample size was based on a previous study by Johnston and colleagues [20]. The laypersons were eligible Department of Defense beneficiaries seeking dental treatment at NPDS, and had no professional background in any aspect of dentistry. The general dentists were trained and licensed in the United States of America, were recruited at NPDS, and had no previous knowledge or relationship to the study.

### Rating of Photographs

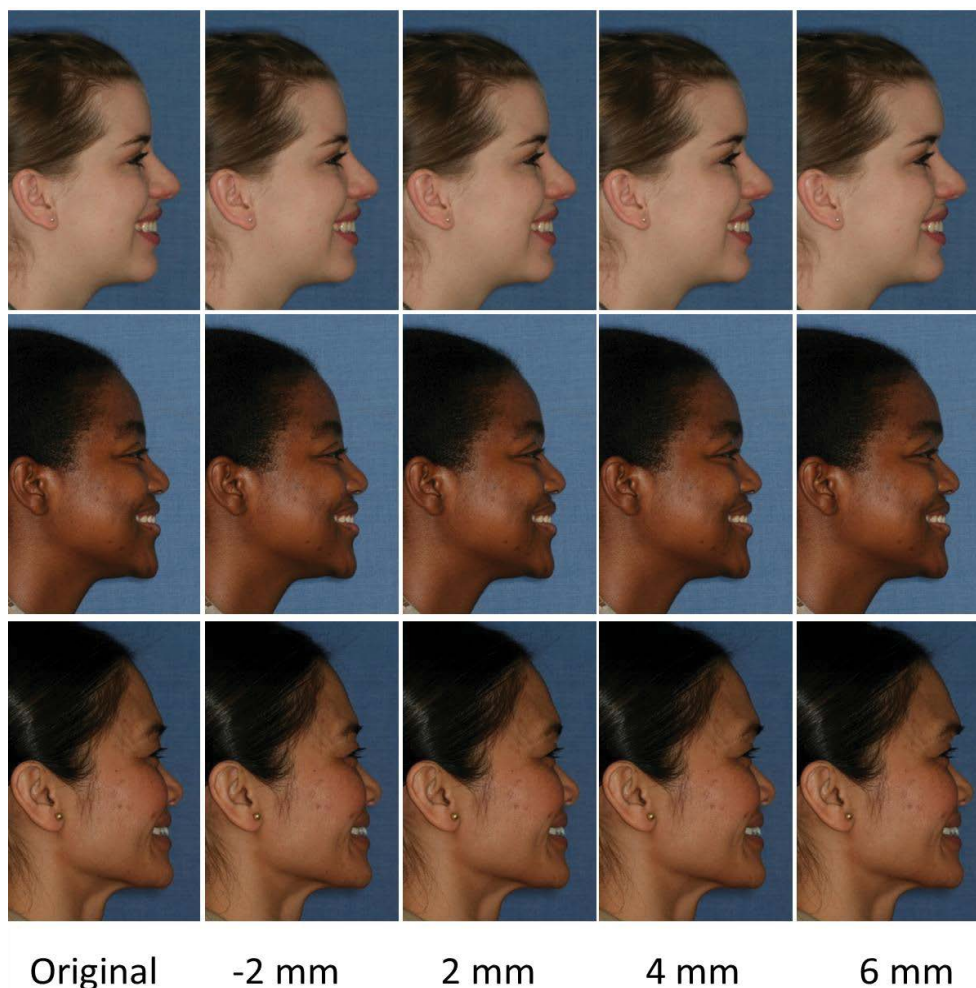
Each judge received the binder of photographs, a 100-mm visual analogue scale (VAS) per photo, and marked the assessment of the model's facial attractiveness to the closest millimeter marking. The same investigator (HE), who was present for all of the 40 sessions, gave the instructions and answered any questions. After the judge acknowledged that he or she understood the instructions, the investigator offered no further guidance. Each judge rated the attractiveness of the 15 photographs by placing a vertical mark along the corresponding VAS line. All of the judges viewed the images in the sequence provided and were not allowed to return to the previously viewed photos conditions [16].

### Data Collection

Each VAS rating was measured from the 0 line using a 100-mm ruler to the closest millimeter increment. Measurements were entered into a Microsoft Excel spread sheet for data analysis.

### Statistical Analysis

The raw scores were standardized to Z-scores as suggested by



**Figure 1:** Original photos and simulated photos from Caucasian (upper panel), African American (middle panel), and Asian (lower panel) models. -2 mm: forehead is moved backward 2mm; 2 mm: forehead is moved forward 2 mm; 4 mm: forehead is moved forward 4 mm; 6 mm: forehead is moved forward 6 mm. In the original photos (Original), all three models have their maxillary incisors naturally placed anteriorly to the soft tissue glabella. After 6 mm advancement of forehead, maxillary incisors are in closer anteroposterior position to the soft tissue glabella.

Johnston, et al. [20]. For each judge, the standardization formula was calculated as suggested by Schlosser, et al. [16].

$$Z \text{ score} = \frac{\text{attractiveness rating of the photograph} - \text{Judge's mean rating score}}{\text{Judge's standard deviation}}$$

For each group of judges (dentist and layperson), all five photos from each model were compared using Friedman's test. If significance was found, further pairwise comparisons of the original to each of the altered photos -- -2mm, +2mm, +4mm, +6mm -- was analyzed using the Wilcoxon signed rank test. The level of significance was set at 0.05 for all statistical tests.

## Results

The mean Z-scores for each model are summarized by the bar graphs in Figures 2-4. The x-axis represents the judge category, dentist versus layperson, and the y-axis represents the mean Z-score. A positive number on the y axis represents an attractive (high) rating on the VAS scale and a negative number represents a less attractive (low) rating on the VAS scale. Table

1 presents the results of the Friedman's test for each model per dentist and layperson. The dentists' results were significant for all of the models. Friedman's test didn't reveal significance for the laypersons, however the results for Caucasian and Asian models were close to the 0.05 significance level (0.056 and 0.058, respectively).

For the Caucasian model, dentists and laypersons showed the highest agreements on the rating of different photos (Figure 2). Photos of original and -2mm are considered most attractive, and the +6mm are the least attractive. In addition, Wilcoxon signed rank test confirmed the significant difference between original and +6mm photos for dentist (Table 2). Although the differences for laypersons are not significant, the trend is similar.

For the African American model, we can see dentists considered original and +2mm are the most attractive, while +2mm and +4mm photos are attractive to laypersons. Both groups of dentists and laypersons rated +6mm as the least attractive (Figure 3).

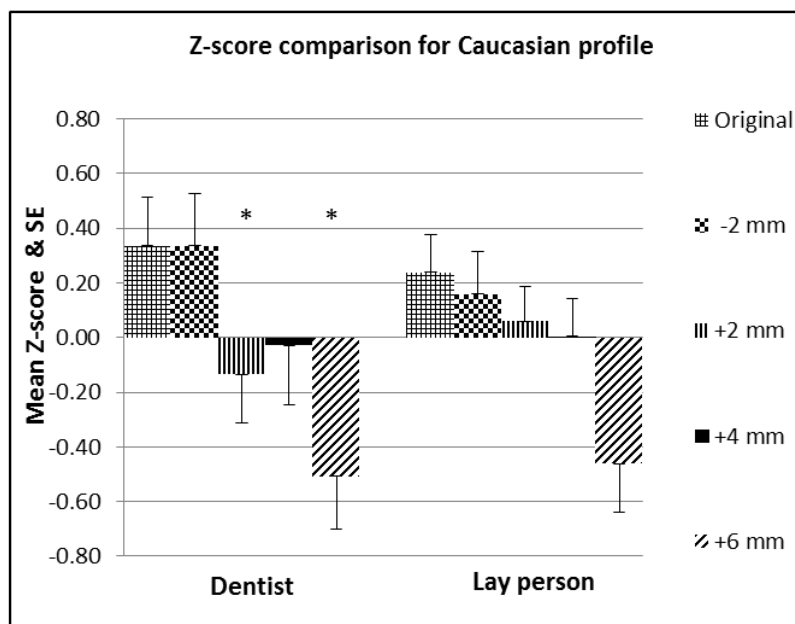


Figure 2: comparison of Z-scores for Caucasian model. \*: P<0.05 when compared with original photo in the dentist group.

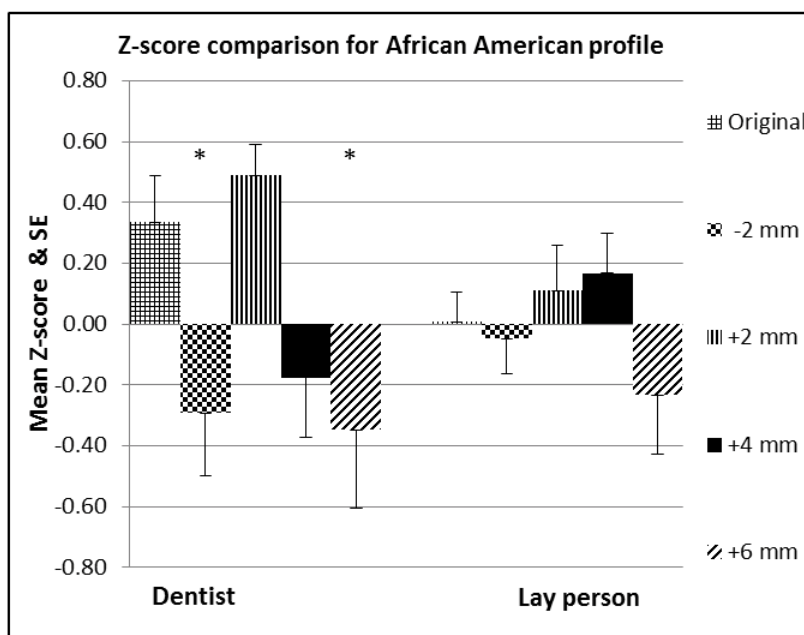


Figure 3: comparison of Z-scores for African American model. \*: P<0.05 when compared with original photo in the dentist group.

For the Asian model, dentists clearly defined the original and +6mm as the most and least attractive photos respectively, however we could not find the similar trend in laypersons (Figure 4).

## Discussion

Previous studies have shown the importance of FFA point

for the anteroposterior position of the maxillary central incisors [10,15-17]. Although Andrews and Andrews advised never to place the maxillary incisors anterior to the soft tissue glabella [9], currently there is no study focused on the effect of soft tissue glabella on the position of maxillary incisors. In this study, we chose to move the forehead instead of only maxillary section as Schlosser, et al. [16] and Cao, et al. [17] and studies, because

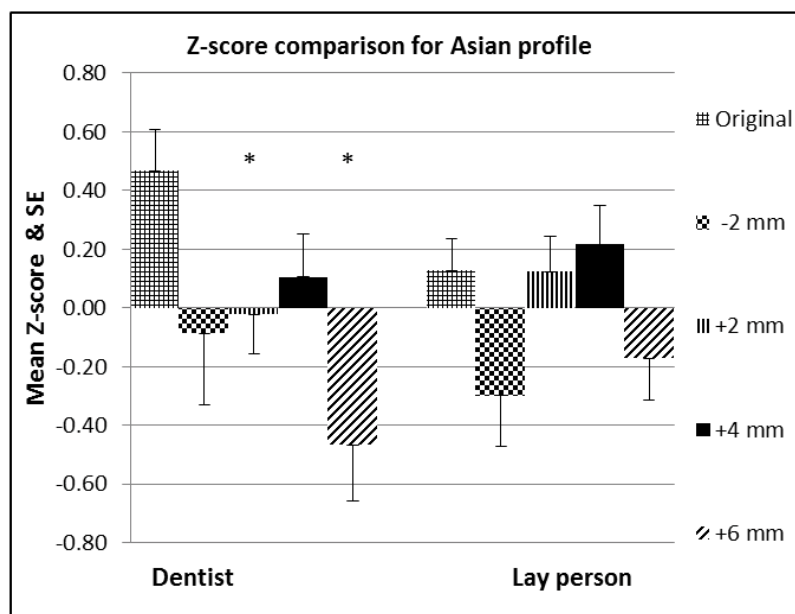


Figure 4: comparison of Z-scores for Asian model. \*: P<0.05 when compared with original photo in the dentist group.

Profile Photos of	P-values using Friedman's test	
	Dentists	Layperson
Caucasian	0.007*	0.056
Asaian	0.042*	0.058
African American	0.003*	0.517

Table 1: Friedman's test for all five photos in each model \*: P<0.05.

	p-values using the Wilcoxon signed ranks test for Pairwise comparison of Original vs.			
	-2 mm	+2 mm	+4 mm	+6 mm
Dentist				
Caucasian	0.95	0.049*	0.397	0.027 *
African American	0.040*	0.639	0.093	0.034 *
Asian	0.121	0.042*	0.176	0.001 *

Table 2: Wilcoxon signed rank test for pairwise comparison between original and other simulation. \*: P<0.05.

in reality we cannot only move forward or backward maxillary section without appropriate similar movement of mandibular section. By simulating forward or backward movement of the forehead, the lower one third of face will be maintained in its original and also the most natural position, which may decrease the disturbance on the rating of attractiveness.

In addition, three models from different races were selected, and the anteroposterior relationship of maxillary incisors and soft tissue glabella were evaluated by both dental professionals and laypersons. Interestingly, although three models originally had their maxillary incisors positioned anterior to the soft tissue glabella, dental professionals and laypersons all selected original photos as (one of) the most attractive. When the forehead was moved forward 6 mm, in the closest anteroposterior position to maxillary incisors, both groups considered it (one of) the least attractive. Therefore, the null hypothesis - there is no difference in the attractiveness after the position of the forehead has changed,

is rejected. Our results do not support the proposal to avoid placing the maxillary incisors anterior to the soft tissue glabella.

It is not surprising to find that dental professionals can detect differences in the altered photos. On the other hand, laypersons didn't show significant differences on rating the altered photos, especially for the African American model. In fact, nearly 50% of the laypersons couldn't tell the difference and rated every photo, the original and all of the altered photos with the same score on the VAS, and one comment that was made by many of the layperson evaluators during this study was that all of the photos for the models looked the same. Another thought is that photographs merely represent a moment in time and fail to provide information in relation to the constantly changing nature of a patient's face. A study by Schabel and colleagues suggested the use of video clips of patients smiling as an alternative method to assess the attractiveness of the model [21]. Using this technique the patients face could be seen from every angle and a more accurate assessment of the attractiveness could be made.

Another interesting finding is that when evaluating the Z-scores it was noted that the Caucasian model was the only model that was appreciated in the similar trend between the dentists and the laypersons. The results showed that the original was considered the most attractive and the +6mm was considered the least attractive for both groups. We were expecting to see similar trends for all of the races as Andrews theorized that the harmony between the maxillary incisors and the forehead should be consistent regardless of ethnicity, gender, or age [14]. However, for African American and Asian models we did not find the high agreement trend as for the Caucasian model. A possible reason is that the majority of the evaluators that participated in the study were Caucasian, which may have introduced some bias toward the African American and Asian models, since the ethnicity of evaluators or judges can influence the perception of esthetics [22]. Another possible explanation is that the Caucasian model

was the only one of the models that had make-up applied for the photo. The other models had blemishes and other distractions. For future studies it would be advisable during the photo alteration to use the blemish removal/ correction tool to remove any possible distractions from the photo as was suggested by Schabel and colleagues [21], or to remove make up as a variable by ensuring that the model photos are taken without make up. Another way to account for this in the future would be to have a more diverse group of evaluators.

## Conclusion

The results of this study reject the null hypothesis, especially for the dentist group. Dental professionals seem to have a sharper eye for details than the laypersons. The attractiveness ratings of the dentists and the laypersons trended similarly between the original and the 4 altered photographs for the Caucasian model. For all three models, the original photo with maxillary incisors anterior to the soft tissue glabella in their unaltered position was the most attractive, and the most extreme change of maxillary incisors being placed 6 mm closer to soft tissue glabella was the least attractive. The findings of this study, suggest that changes of AP position of the soft tissue glabella impact the appreciation of facial attractiveness. Our data does not support the proposal that dentists should avoid placing the maxillary incisors anterior to the soft tissue glabella.

## Acknowledgement

The authors would like to thank Nan Lu, the IT specialist at NPDS, for her assistance on the image manipulation.

## References

1. Arnett GW, Gunson MJ. Facial planning for orthodontists and oral surgeons. *Am J Orthod Dentofacial Orthop.* 2004;126(3):290-295.
2. Spyropoulos MN, Halazonetis DJ. Significance of the soft tissue profile on facial esthetics. *Am J Orthod Dentofacial Orthop.* 2001;119(5):464-471.
3. Tweed CH. The Frankfort-mandibular incisor angle (FMIA) in orthodontic diagnosis, treatment planning and prognosis. *Angle Orthodontist.* 1954;24(3):121-169.
4. Ricketts RM. Esthetics, environment, and the law of lip relation. *Am J Orthod.* 1968;54(4):272-289.
5. McNamara JA Jr. A method of cephalometric evaluation. *Am J Orthod.* 1984;86(6):449-469.
6. Holdaway RA. A soft-tissue cephalometric analysis and its use in orthodontic treatment planning. Part I. *Am J Orthod.* 1983;84(1):1-28.
7. Holdaway RA. A soft-tissue cephalometric analysis and its use in orthodontic treatment planning. Part II. *Am J Orthod.* 1984;85(4):279-293.
8. Arnett GW, Jelic JC, Kim J, et al. Soft tissue cephalometric analysis: diagnosis and treatment planning of dentofacial deformity. *Am J Orthod Dentofacial Orthop.* 1999;116(3):239-253.
9. Andrews LF, Andrews WA. Syllabus of the Andrews Orthodontic Philosophy, 9<sup>th</sup> edition San Diego, CA, The Lawrence F. Andrews Foundation. 2001.
10. Andrews WA. AP relationship of the maxillary central incisors to the forehead in adult white females. *Angle Orthod.* 2008;78(4):662-669.
11. Antoszewski B, Sitek A, Kruk-Jeromina J. Analysis of nose growth. *Otolaryngol Pol.* 2005;59(6):925-931.
12. Kushimoto K. Study on the growth of the nose. *Gifu Shika Gakkai Zasshi.* 1990;17(1):100-123.
13. Kasai K. Soft tissue adaptability to hard tissues in facial profiles. *Am J Orthod Dentofacial Orthop.* 1998;113(6):674-684.
14. Andrews LF, Andrews WA. The six elements of orofacial harmony. *Andrews Journal.* 2000;1(1):13-22.
15. Adams M, Andrews W, Tremont T, et al. Anteroposterior relationship of the maxillary central incisors to the forehead in adult white males. *Orthodontics (Chic).* 2013;14(1):e2-9.
16. Schlosser JB, Preston CB, Lampasso J. The effects of computer-aided anteroposterior maxillary incisor movement on ratings of facial attractiveness. *Am J Orthod Dentofacial Orthop.* 2005;127(1):17-24.
17. Cao L, Zhang K, Bai D, Jing Y, Tian Y, Guo Y. Effect of maxillary incisor labiolingual inclination and anteroposterior position on smiling profile esthetics. *Angle Orthod.* 2011;81(1):121-129.
18. Fitzgerald JP, Nanda RS, Currier GF. An evaluation of the nasolabial angle and the relative inclinations of the nose and upper lip. *Am J Orthod Dentofacial Orthop.* 1992;102(4):328-334.
19. Kokich VO, Kokich VG, Kiyak HA. Perceptions of dental professionals and laypersons to altered dental esthetics: Asymmetric and symmetric situations. *Am J Orthod Dentofacial Orthop.* 2006;130(2):141-151.
20. Johnston CD, Burden DJ, Stevenson MR. The influence of dental to facial midline discrepancies on dental attractiveness ratings. *Eur J Orthod.* 1999;21(5):517-522.
21. Schabel BJ, Baccetti T, Franchi L, McNamara JA. Clinical photography vs digital video clips for the assessment of smile esthetics. *Angle Orthod.* 2010;80(4):490-496.
22. Chong HT, Thea KW, Descallar J, et al. Comparison of White and Chinese perception of esthetic Chinese lip position. *Angle Orthod.* 2014;84(2):246-253.