

Vesico-ureteric reflux [VUR]

This article was published in the following Scientific Open Access Journal:

Journal of Integrative Pediatric Healthcare

Received March 06, 2018; **Accepted** March 06, 2018; **Published** March 12, 2018

Sivasankar Jayakumar^{1*}

¹Professor, Department of Paediatric Surgery,
University Hospitals Leicester, Leicester, UK

Vesico-ureteric reflux [VUR] is abnormal retrograde flow of urine from the bladder to the upper urinary tract. VUR is the most common urological anomaly associated with UTI in children. Majority of VUR are primary/congenital, however they can occur secondary to other pathologies causing bladder outlet obstruction.

Incidence

It is seen in almost 31 – 37% of children presenting with UTI symptoms and in 1-2% in the general population. The incidence is much higher in boys under the age of 1 year while the incidence is reported to be higher in girls above the age of 1 year.

Grading

The international reflux grading system classifies VUR into 5 grades – I to V. The classification is based on the radiological findings on MCUG scan [Figure 1]. Grade 1 and 2 are reflux limited to the lower ureter and considered as mild, grade 3 to 5 are considered significant and surgical intervention is usually recommended.

Aetiology

It is still unclear what the exact aetiology is behind VUR. The basis for VUR is considered to be primarily genetic, with a 30-50% incidence of VUR in first-degree relatives of patients. A meta-analysis of articles in literature revealed a mean incidence of reflux in siblings in all studies as 32%. In a study on 215 index patients with VUR, the incidence of sibling VUR is maximal in patients who are younger than 3 years. The study recommends screening all siblings who are younger than 3 years of index patients with high grades (III to V) of VUR.

Developmentally, VUR arises from disruption of complex signalling pathways and cellular differentiation. These mechanisms are probably genetically programmed but may be influenced by environmental exposures. A locus on chromosome 5 has been shown in familial inheritance of VUR, however multiple genes are likely to contribute to the formation of VUR phenotype.

Majority of VUR are primary with a congenital pathology. However, VUR can be secondary due to raised or dysfunctional bladder pressures as seen in posterior urethral valves, bladder diverticulum, neuropathic bladder and voiding dysfunction syndromes. Ectopic ureters associated with ureterocele and duplex system can also lead to significant VUR.

Pathophysiology

During micturition the urinary bladder contracts, while the bladder outlet is closed raising the intravesical pressure. The oblique insertion of ureters into the urinary bladder trigone creates a sub mucosal tunnel that closes with the raised intravesical pressure during micturition and thereby prevents the urine flowing back into the ureters. This structural anatomy is altered in children with VUR and therefore urine refluxes into either one or both the ureters.

There are 2 types of renal papillae – simple and compound. The compound ones are seen in both upper and lower poles while the simple ones are seen in the middle portion of the kidneys. The simple papillae have a slit like mechanism that prevents back flow of the intra renal reflux and therefore remain unaffected at the early stages of reflux nephropathy. The compound papillae however are more gaping and lack the

*Corresponding Author: Sivasankar Jayakumar,
Professor, Department of Paediatric Surgery,
University Hospitals Leicester, Leicester, UK, Email:
shivajayakumar@gmail.com

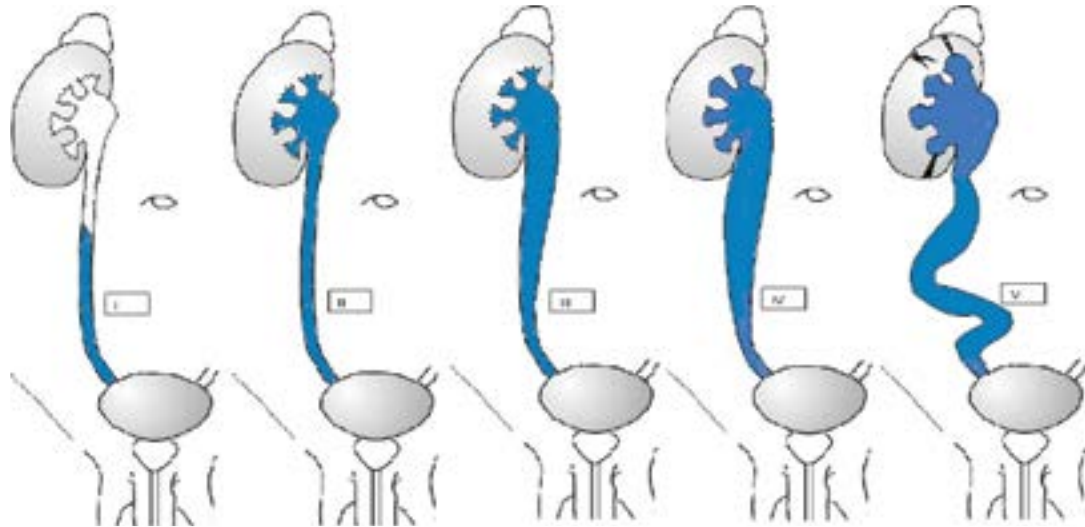


Figure 1: Classification of grades of vesicoureteral reflux adopted from the International Reflux Study Committee.

Grade I: reflux into ureter only.

Grade II: reflux into ureter, pelvis, and calyces. There is no dilation, and calyceal fornices are normal.

Grade III: mild or moderate dilation, and/or tortuosity of the ureter and moderate dilation of the renal pelvis but little or no blunting of the fornices.

Grade IV: moderate dilation and/or tortuosity of the ureter and moderate dilation of the renal pelvis and calyces.

Grade V: gross dilation and tortuosity of the ureter and gross dilation of the renal pelvis and calyces. There is complete obliteration of the sharp angle of the fornices.

slit like mechanism and therefore more susceptible to reflux nephropathy. This explains why renal scarring is particularly noted in the upper and lower poles of the kidney.

Diagnosis

VUR by itself does not produce any clinical signs and symptoms and therefore most children and infants with VUR are asymptomatic unless complicated with a UTI. VUR should be suspected in infants and younger children presenting with febrile UTI or recurrent UTI. In older children who can communicate clearly a history of recurrent UTI and pyelonephritis should raise a suspicion of VUR secondary to other pathology.

The NICE guidelines UK recommend that all children presenting with UTI under the age of 6 months should undergo an USS, MCUG and DMSA scan. USS is a valuable non-invasive investigation that can reveal dilated renal pelvis [Hydronephrosis] or as in case of high grade VUR ipsilateral hydronephroters can also be seen. Grade 1 and 2 VUR are not appreciated on USS. Pre and post micturition bladder volumes are helpful in diagnosing bladder dysfunction which could be the underlying cause for VUR. Impaired renal growth and renal scarring secondary to reflux nephropathy are well appreciated on USS and therefore USS is a valuable tool in following patients with VUR.

VUR is well recognized on MCUG (Micturating cystourethrogram) scan and it is the gold standard diagnostic test. However this test is invasive and not easy to perform unlike an USS. It requires catheterisation of the bladder, injecting contrast and taking images while the child is micturating. Compliance is an issue in children; but infants tolerate the procedure well. MCUG not only reveals the grade of reflux, but can also provide valuable information on bladder neck and urethra and identify secondary causes of VUR. The sonographic diagnosis of VUR with contrast-enhanced voiding urosonography (VUS) has been reported but this has not gained popularity.

Nuclear renal imaging involves injection of radio-isotope material and obtaining images as and after renal uptake and excretion. DTPA/MAG3 scan can also be used as an indirect cystogram and can reveal VUR. However its use is more in identifying obstruction and drainage patterns of the renal tract. DMSA scan on the other hand adds valuable information on renal function and revealing renal scarring. Timing of these scans is particularly important and should not be carried out within the first 3 months after a febrile UTI. If done earlier results may be inaccurate.

Management

Preservation of upper tracts and renal function forms the mainstay of management in children with VUR. The damage from VUR alone is far less and preventing UTI is the key to preserve existing renal function. Almost in a third of the children diagnosed with VUR, the reflux resolves spontaneously but in a third it remains static and in the remaining it progresses to cause severe renal damage. In infants and younger children the submucosal tunnel of ureter is short and more straight, but as the children grow the length of the tunnel increases and also the bladder pressure and volumes alter. This change possibly explains the spontaneous resolution of VUR in some children. The grade of reflux is the strongest predictor of VUR resolution, with high-grade VUR being much less likely to resolve.

The most worrying outcome of VUR is reflux nephropathy [RN]. Patients with VUR may develop renal scarring and impaired renal growth which collectively is referred to as reflux nephropathy [RN]. Reflux nephropathy leads to impaired renal function, hypertension, and proteinuria. A combination of UTI along with high grade reflux is known to cause RN. However studies on animals have shown that high grade reflux without UTI could also induce RN (Ransley et al, 1984). The grade of reflux, history of urinary tract infection and age at diagnosis are the

most significant independent risk factors for renal parenchymal damage.

Role of antibiotics

Traditionally continuous use of prophylactic antibiotics like Trimethoprim, Cephalexin and Nitrofurantoin has been used to reduce the incidence of UTI in children with VUR and thereby preventing subsequent renal damage. However the use of prophylactic antibiotics has been recently questioned and it's debatable if it will benefit the children with VUR. Literature review reveals conflicting results from different studies. In a recent systematic review by Dai et al, the analysis on 2046 patients over 11 trials suggested that the rates of recurrent symptomatic UTI were not significantly different between antibiotic (12.4%) and control groups (15.5%). However, prophylactic antibiotics reduced the risk of repeat positive urine culture. Large scale, high quality, placebo-controlled, double-blind randomised trials are required to form conclusive evidence on use of antibiotics. Currently, it is an acceptable practice to recommend prophylactic antibiotics in children with high grade VUR (III – V).

Role of surgery

Indications for surgical intervention includes high grade reflux, failed conservative management, bilateral VUR, recurrent breakthrough UTI, older children and persistent

reflux after the age of 5 years. Options for surgical intervention include open correction of reflux and endoscopic correction. The main principles behind open surgical correction are mobilisation of the refluxing ureter and increasing the submucosal intravesical tunnel and thereby preventing reflux. Various open surgical techniques for correcting VUR, popularised by Cohen, Leadbetter, Paquin, Hutch, Lich and Gregoire, Daines and Hudson, Politano and Glenn and Anderson have been described.

Endoscopic correction of VUR is relatively a new surgical approach. The first data on experimental Endoscopic correction of VUR with Teflon injection (STING) in piglets was published in 1984. Since then this technique has popularised and widely being used for correction of VUR. The technique involves injection of an inert substance – Teflon into the submucosa behind the ureteric orifice, entering the bladder endoscopically. A study on 91 children showed nearly 80% success rate following single injection of Teflon. In the subsequent years TEFLON injection has been replaced by DEFLUX, which was first introduced in 1998 for injection in vocal cord insufficiency. However, the reported success rates of endoscopic correction vary significantly. Multiple injections at different intervals could be tried in the event of recurrence of VUR. Although the endoscopic correction is a simple, a less invasive technique, the recurrence rate of reflux is slightly higher than open surgical techniques.