

Atypical findings of kikuchi-fujimoto disease

Ravneel Gulati*, Diane Badin, Amer Syed, Simon Badin and Qing Lin

Department of medicine, Jersey city medical center, USA

This article was published in the following Scient Open Access Journal:

Clinical Microbiology & Case Reports

Received December 23, 2014; **Accepted** January 22, 2015; **Published** February 03, 2015

Abstract

Kikuchi-Fujimoto disease, histiocytic necrotizing lymphadenitis is a condition of unknown cause characterized by fever and cervical lymphadenopathy. This case describes a 22 year old female afebrile, presenting with bilateral anterior cervical lymphadenopathy. The findings of the case are important because of the disease's rarity, clinical features and unidentified etiology.

Case Report

A 22 year old Dominican female was admitted to Jersey City Medical Center for generalized body and neck pain, fronto-parietal headache with associated left eye pain, and burry vision. The patient had been well until three weeks prior to admission, when she developed tender cervical lymphadenopathy. Two days preceding admission she presented to her primary care doctor's office where blood work and computed tomography scan of her neck and chest were ordered however, due to worsening symptoms of fatigue, fronto-parietal headache and neck pain, she returned to her primary care doctor prior to completion of her tests. Ibuprofen was prescribed for pain but it did not improve her situation and she was admitted to the hospital for further assessment.

The patient had no complaints of night sweats, fever, chills and sore throat. Patient has a medical history of lower back pain, hypothyroidism and vitamin D Deficiency and previous cholecystectomy in 2012. She takes prescribed Ibuprofen, Vitamin D₃, and Levothyroxine and has no known history of allergies to food or medication. The patient was born in the Dominican Republic and immigrated to the United States prior to starting high school. She worked as child day care teacher and lives with her husband, two daughters, sister, mother-in-law, and has no known exposure to pets. Patient consumes 4 to 8 ounces of alcohol every other weekend, does not smoke or ingest tobacco products, and no history of illicit substance use. Her mother died from a fatal myocardial infarction at the age of 38 years and her father suffers from asthma. However, there is no family history of connective tissue diseases.

On examination, the temperature was 37.5°C, blood pressure 122/71 mm Hg, pulse of 89 beats per minute, respiratory rate of 16 breaths per minute, and oxygen saturation of 99% on room air. Right and left anterior cervical chain lymph nodes of the neck measured 1.5 cm in length. Lymph nodes were red, tender, and warm to palpation on the left and painless upon palpation on the right. Lymph nodes in the supraclavicular and axillary region were not appreciable. Abdomen was scaphoid in appearance, soft and non-tender upon palpation with no hepatosplenomegaly. The remainder of the physical examination was unremarkable. Patient was placed under neutropenic precautions due to severe neutropenia. TSH and TPO antibodies were elevated. Urine analysis, liver, and renal function tests were normal. Connective disease work-up revealed negative results as were the results for EBV viral capsid antigen and antibodies IgG, IgM, hepatitis B surface and core antigens, hepatitis C antibodies, hepatitis A antibodies, rapid plasma reagin, parvovirus antigens, and HIV western blot and viral load (Table 1).

CT scan of neck, thorax, abdomen and pelvis showed multiple mildly prominent lymph nodes present throughout the neck including levels Ia and Ib, levels II, levels III, IV, and V. The largest nodes were at level V where a left node, measured 14 x 9 mm and a left level Vb node measured 16 x 14 mm. There were bilateral parotid lesion lymph nodes measuring 8.6 x 13 mm on the right and 9.3 x 7.6 mm on the left. Multiple bilateral axillary lymph nodes were also present but no nodal necrosis. There was no acute process in the abdomen or pelvis.

*Corresponding author: Ravneel Gulati, Department of medicine, Jersey city medical center, USA, Email: ravneel.gulati@gmail.com

Comprehensive Basic Panel		Connective Tissue Work Up		Thyroid Work Up	
WBC	2.4 x 10 ³ /μL	Anti-CCP	5.0 units	Thyroid Stimulating Hormone	13.81 μIU/mL
Neutrophils	32%	Anti-dsDNA Antibody	8.0 IU/units	TPO Antibodies	>1000 μIU/mL
Lymphocytes	53%	Anti-Histone Antibody	0.5 units	Thyroid Stimulating Hormone	38.58 μIU/mL
Monocytes	15%	Uric Acid	3.7 mg/dL	T3	1.3 ng/mL
		Antinuclear Antibody	Negative		
		ESR	21 mm/hr		

**Urine Analysis, Liver and Renal Function tests Normal
 ***Infection work up for Epstein Virus Antigen and Antibodies IgG and IgM, Hepatitis B surface and core Antigens, Hepatitis C Antibodies, Hepatitis A Antibodies, Rapid Plasma Reagin, Parvovirus Antigens, and HIV western Blot and viral load revealed negative results

Table 1: Significant Lab Findings

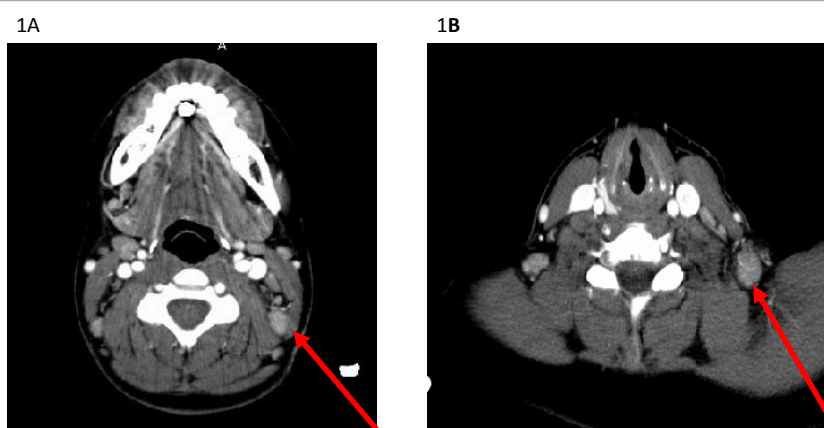


Figure 1A: The largest nodes were at level v where a left node, measured 14 x 9 mm; and Figure 1B: left level Vb node measured 16 x 14 mm.

*There were bilateral parotid lesions, lymph nodes measuring 8.6 x 13 mm on the right and 9.3 x 7.6 mm on the left. Multiple bilateral axillary lymph nodes were also present but no nodal necrosis

During the course of hospitalization the patient became febrile, for which intravenous antibiotics were initiated immediately for neutropenic fever. Blood and urine cultures were sterile on two different occasions. Cervical lymph node biopsy revealed necrotizing lymphadenitis. Acid Fast Bacillus stain for mycobacterium was negative. Grocott-Gomori's Methamine Silver Stain for fungus was also negative. A bone marrow biopsy was also performed revealing 40% trilineage hematopoiesis, presence of megakaryocytes in adequate numbers without atypia, slight mild increase in eosinophilic infiltrate however; no evidence by flow cytometry analysis or morphology of lymphoma, acute leukemia, or high grade myelodysplastic syndrome.

Based on all the presenting signs and symptoms as well as results from lab work up including infectious and connective tissue causes; the final diagnostic outcome, after thorough exclusion; resulted from histopathological images from the biopsied lymph node. The histology of the biopsied lymph node exhibited histiocytic infiltration and karyorrhectic necrotic debris, classic for Kikuchi-Fujimoto disease. Furthermore, the patient was treated with intravenous antibiotics and received supportive care including intravenous hydration and analgesics. Patient's symptoms gradually resolved and she was discharged for outpatient follow up (Figure 2) [1].

Differential Diagnosis

Although the presentation, signs and symptoms may be non-

specific it is likely to misdiagnose KFD to other diseases such as Systemic Lupus Erythematosus, lymphoma, or infectious causations [2]. It's important to distinguish Hodgkin's lymphoma from KFD because classic histological features for both diseases present with necrosis and histiocytic infiltration but the presence of Reed-Sternberg cells distinguishes Hodgkin's lymphoma from KFD [3]. Distinguishing non-Hodgkin's lymphoma from KFD is difficult however, the key factor to keep in mind is that in KFD CD8+T cells are predominant whereas in Non-Hodgkins Lymphoma CD4+T cells predominate [3].

One of the most challenging differentials include systemic lupus erythematosus in that histopathological presentations of lymph node biopsy may present identical to KFD however, SLE lymphadenitis contains hematoxylin bodies (i.e. nuclear debris) that aggregate near blood vessel walls [3]. Other considerations when distinguishing KFD from SLE lymphadenitis are connective tissue work up especially antibodies against double stranded DNA and complement levels C3 and C4 [3].

Currently, there are several infectious causes that could be linked to or mimic KFD however, the key distinguishing feature from viral lymphadenitis and KFD is that viral lymphadenitis contains less histiocytic but prominent neutrophilic and plasma proliferation. For an example some herpes simplex viral infection can be easily distinguished from KFD via viral inclusions [3]. Epstein Bar Virus can present similarly to KFD especially with

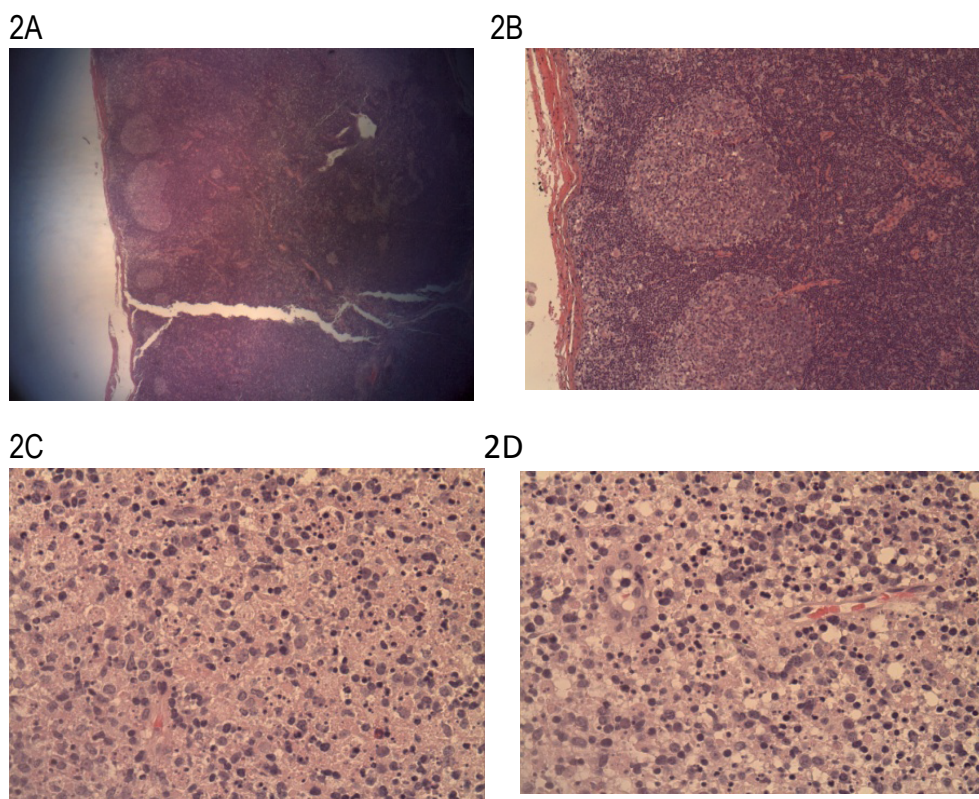


Figure 2A: low magnification of the lymph node showing reactive follicles, **2B** higher magnification of reactive follicles and preservation of the lymph node; **2C** and **2D** both displaying higher magnification with histiocytic infiltration and karyorrhectic debris.

cervical lymphadenopathy however, histological features of EBV include follicular hyperplasia, prominent B cells, plasma cells and several necrotic areas [3].

Discussion

Kikuchi's disease, also called Kikuchi-Fujimoto disease or Kikuchi's histiocytic necrotizing lymphadenitis, was originally described in the early 1970's in Japan commonly in young women. It is a rare, benign condition of unknown cause usually characterized by cervical lymphadenopathy and fever. Histopathology of the involved lymph nodes differentiates Kikuchi's disease from several more serious conditions that it may mimic. We present a case of young female who presented with sudden onset of symptoms with fever and lymphadenopathy. KFD is a benign histiocytic necrotising lymphadenitis. KFD is rare, but most common in Asia. In the early 1970s both Kikuchi and Fujimoto first described cases of KFD in Japan [1]. Its etiology has not yet been fully determined, however it is believed it may be of viral origin, EBV, HHV6 and 8 have been suggested. Certain signs and symptoms, although non-specific include lymphadenopathy, fever, sweats, malaise, anorexia, weight loss, hepatomegaly and leukopenia however, a definitive diagnosis is made by lymph node tissue biopsy [2].

Previous cases of patients have presented 2 to 6 weeks with unilateral submandibular, supraclavicular, and axillary lymphadenopathy with fever and abdominal symptoms [2,3]. Some cases present with bilateral cervical lymphadenopathy with fever, weight loss and abdominal pain and diarrhea [4].

Another case involved a woman who had unilateral cervical lymphadenopathy for over 10 months including arthritis in and arthralgia. Like many cases women are young from Asia, Middle East and Eastern European countries [4].

Our case differs from others in that our patient is from Dominican Republic and did not present with a fever but did present with bilateral cervical lymphadenopathy. What sets this case from others is that the primary complaint was severe fatigue and headaches with no night sweats, fever, hepatosplenomegaly or weight loss; although many patients with KFD do present with non-specific symptoms. The main characteristic feature in this case was bilateral cervical lymphadenopathy with blood work revealing severe neutropenia and a severely low white blood cell count that has not been seen in other research. This is important because although the disease is rare it is not limited to only young women from Asia, Eastern European or Middle Eastern areas. KFD is still of unknown origin and more research needs to be funded to understand the origin of the disease. Differentials are very important to consider in that KFD continues to mimic other diseases such as autoimmune disorders, cancer as well as infectious manifestations. In most cases KFD is symptomatic with spontaneous recovery or sometimes recovery through supportive care. Although, most patients with KFD may present with lymphadenitis there are some that may not present with visible lymphadenitis and complain of non-specific symptoms. In most cases KFD is a diagnosis of exclusions because it mimics many diseases like lymphoma SLE, EBV etc., therefore; a thorough work up is vital because KFD can be easily missed or

misdiagnosed. More research and attention should be directed towards searching and understanding the etiology and origin of the disease and its inherent ability to mimic known infections, autoimmune disorders and cancers such as lymphoma.

References

1. Bosch X & Guilabert A. Kikuchi-Fujimoto Disease. *Orphanet Journal Rare Disease*. 2006,1(18);1-3.
2. Mahajan T, Merriman RC & Stone MJ. Kikuchi-Fujimoto Disease (histiocytic necrotizing lymphadenitis): report of a case with other autoimmune manifestation. *Proc(Baylor University Medical Center)*. 2007,20(2): 149-151.
3. Hutchinson CB & Wang E. Kikuchi-Fujimoto Disease. *Archives of Pathology & Laboratory Medicine*. 2010,134;289-292.
4. Duskin-Bitan H, Kivity S, Olchovsky D, Shiby G, Ezra D, Mouallem M. *IMAJ*. 2010,12;616-620.