Clinical Microbiology & Case Reports

ISSN: 2369-2111

Case Report

Varicella zoster virus related vasculopathies: Role of prompt diagnosis and immediate treatment in preventing mortality and morbidity

This article was published in the following Scient Open Access Journal:
Clinical Microbiology & Case Reports
Received December 26, 2014; **Accepted** January 15, 2015; **Published** February 03, 2015

Shivani Garg[1]*, Julie Lai[1] and Antonette Climaco[2]

[1]Department of internal medicine, Einstein medical center, Philadelphia, USA; [2]Department of infectious diseases, Einstein medical center, Philadelphia, USA

Abstract

A 54 year-old female known with HIV, presented with acute onset of fever, targetoid lesions on extremities and peripheral acute retinal necrosis was seen on fundoscopy. MRI and CSF findings supported the diagnosis of varicella zoster (VZV) encephalitis and acyclovir was promptly started and improvement was noted. Varicella zoster vasculopathy was confirmed by the presence of varicella antibody in CSF which took several days.

Keywords: Varicella zoster, Vasculopathy, Retinal necrosis

Introduction

Varicella zoster vasculopathy is a rare, yet fatal disease in HIV patients. Recognizing theperipheral vascular manifestations can help in early diagnosis and prompt treatment.

Case Report

Our patient was a 54 year old African American female who presented with fever and altered mental status. Patient was accompanied with her daughter who was historian in this case. As per the historian, patient was witnessing high grade fever for last three to four days and fever was not associated with any headaches, rigors or chills. Family noticed that the patient was slower than her usual self and confused for last few days. Daughter mentioned that patient was unable to recollect events occurred in the recent past and also she was not oriented to time and place. On further questioning, she mentioned that she noticed that patient preferred to stay in dark room and also few days back she mentioned some blurring of vision. As per historian, patient was diagnosed with Human immunodeficiency virus (HIV) 2 years ago and was taking medications for same. Further investigation revealed that she was non complaint with her medications and her last follow up was 8-10 months ago and her CD4 count was 245 mm/ml during that visit. According to the historian, patient was in good health for last 8 months and was never treated for any opportunistic infections or hospitalized in recent past. Her review of systems was negative. On detailed physical examination clinicians noticed patient was suffering from fever (103F) and was tachycardic (126 beats per min). Diffuse targetoid lesion was observed on patient's extremities (as shown below). Patient was arousable and oriented to person, meningism was noticed and no other neurological deficits were observed. Her fundus examination revealed retinal necrosis more prominent on periphery as compared to central retina (see below) supporting varicella zoster infection. Based on the above findings a differential diagnosis of herpes simplex virus (HSV) encephalopathy, varicella zoster virus (VZV) encephalopathy, other viral or bacterial causes of encephalopathy were higher on the list but as patient was immunocompromised other opportunistic infections like toxoplasmosis, CNS lymphoma etc needed to be ruled out. Besides basic laboratory work up, patient's cerebrospinal fluid (CSF) was examined which revealed elevated proteins, few red blood cells (RBCs) in a non traumatic lumbar puncture and lymphocyte predominant white blood cells (WBCs) pleocytosis. Also polymerase chain reaction (PCR) for HSV and VZV were done which were negative and antibody titers for above were pending. To rule out other infection and structural lesions as mentioned above, magnetic resonance imaging (MRI) was done which showed diffuse scattered small infarct (see below). Biopsy of skin lesions revealed erythema multiforme lesions. Based on the indicators like progressive outer retinal necrosis (PORN) on fundus exam, CSF indicating viral infection, MRI supporting small vessel infarcts and skin biopsy results, in setting of negative PCR for HSV VZV encephalopathy was suspected and patient was started on intravenous acyclovir. Patient improved clinically. 7 days after start of treatment, diagnosis

***Corresponding author:** Shivani Garg, Department of internal medicine, Einstein medical center, Philadelphia, USA, Tel: (215) 456-8520, Fax: (215) 456-7926, E-mail: shivanigarg88@yahoo.co.in

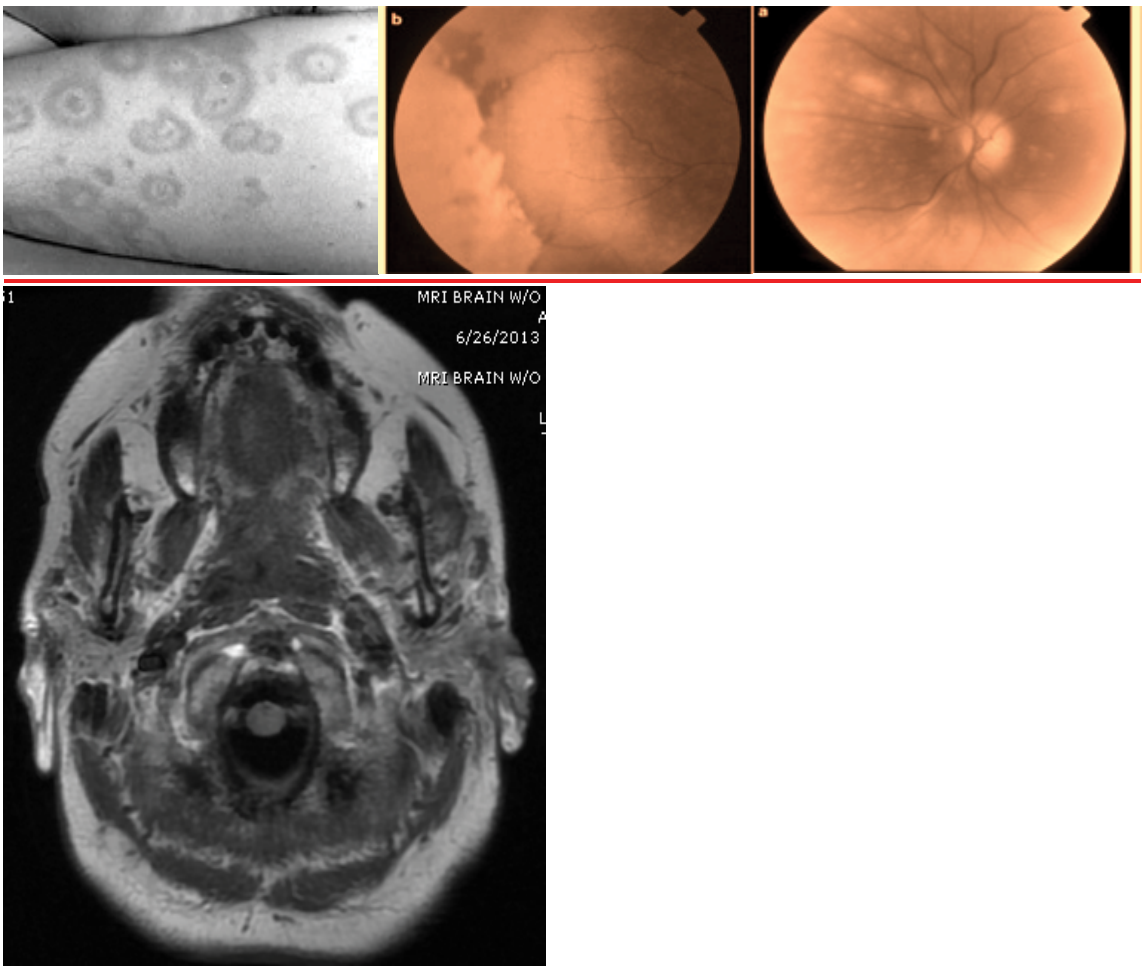

Figure 1. A) Targetoid lesions on lower extremities, on skin biopsy erythema multiforme lesions. **1B & 1C)** Fundus examination revealing Progressive Outer Retinal Necrosis (PORN). **1D)** MRI showing diffuse scattered small lesions at grey-white junction indicating varicella zoster virus encephalopathy as one of the differential.

was confirmed by presence of VZV antibody (IgM) in patient's CSF (Figure 1).

Discussion

Varicella zoster is caused by a highly neurotropic alphavirus which remains dormant in cranial nerve ganglion and upon reactivation it causes a wide spectrum of diseases like myelitis, retinitis, zoster sine herpete or other neurological complications like stroke, intracranial hemorrhage (ICH) etc., [1-3].

Retrograde trans-axonal spread along the afferent nerves supplying ganglion and lies dormant in the ganglion for years till the time virus gets reactivated due to weakened immunity of the host either due to aging or other acquired immunodeficiency states [4]. Once activated, the virus causes inflammation of the vessels supplying the ganglion which is demonstrated by abundance of multinucleate giant cells and monocytes in the vessel walls on histopathology sections [1,3,4]. Further on these sections central cavitation after necrosis and abundance of macrophages around central necrotic area have been noticed and inclusion bodies are described in high number in the small vessel vasculitis as compared to large vessel vasculitis. Inflammation leads to thrombosis and eventually presents as transient ischemic attack (TIA) or stroke. Although zoster can happen anywhere in the body but a predilection to central and peripheral nervous system is observed [1]. Many researchers believe substance P (a neurotransmitter present in the ganglion and nerves) has a role in migration of virus from the afferent nerves to affected ganglion as high levels of above are found in the nerve roots and ganglions affected by varicella zoster [4]. Cases so far reported describe a multifocal presentation of varicella zoster vasculopathy with equal large and small vessel involvement with predilection for posterior circulation with or without rash or skin findings [1,3,4].

First case was studied by Cravioto and Feigin, 55 years ago and they labeled varicella zoster as non-infectious granulomatous disease with a predilection for the nervous system, characterized by thrombosis of arteries and was different from other vasculitidies as vessel wall had multinuclear giant cells, monocytes and histiocytes as the inflammatory cells. Rosenblum and Hadfield also highlighted the granulomatous response in the vessels supplying the affected ganglions secondary to varicella zoster virus in immunocompromised and cancer patients [1,3,4]. First diagnostic test was cerebral angiography which supported the evidence of inflammation of vessels rather than invasion of ganglion by revealing segmental arteritis.

Older cases describe large arteries to be a more susceptible target of varicella zoster virus and hence presents commonly as contralateral hemiparesis or transient ischemic attack. Unlike the previous known acute hemiplegia cases from large artery disease, the clinical range has expanded from transient ischemic attack (TIA) or contralateral hemiplegia to myelitis, cerebellitis, aneurysm and intracranial hemorrhage secondary to artery ectasia and polyneuritis cranialis and now varicella zoster vasculopathy is defined as a protracted disease involving both small and large cerebral arteries.

In comparison with previously described cases of herpes zoster and vasculopathy, clinical range of this disease has expanded to include TIA, myelitis, zoster sin herpete, polyneuritis cranialis, radiculopathy, cerebellitis, various eye presentations like central retinal artery occlusion (CRAO), acute retinal necrosis (ARN) and progressive outer retinal necrosis (PORN) [5,6]. Immunocompromised patients irrespective of the cause of immunosuppression have a complex clinical presentation and poor prognosis as compared to immunocompetent patients. Varicella zoster has a multifocal presentation with both small and large vessel involvement and based on the areas affected the symptoms evolve. The most common presentation is contralateral hemiparesis usually seen after herpes zoster ophthalmicus involving the trigeminal nerve distribution [1,3-5]. Other common presentation is altered mental status, multifocal weakness due to infarcts which are typical seen in anterior and posterior circulation distribution and visual symptoms like sudden loss of vision, flashes, floaters, veil in vision and photopsia which are seen after either CRAO or Retinal necrosis [3,4]. Other forms of presentation is based on the area involved like spastic paralysis after spinal cord involvement, cerebellar ataxia after inflammation of cerebellum and neuropathy like symptoms (neuropathic pain and patchy weakness) after involvement of different nerve roots supplied by the similar artery like X,XI,XII cranial nerves (supplied by ascending pharyngeal artery) or III, IV, V1, V2 cranial nerves (supplied by internal carotid artery in the cavernous sinus) which is labeled as polyneuritis cranialis [2-4]. Majority of these symptoms are not associated with rash neither are preceded by skin involvement in the form of typical zoster rash with the exception of contralateral hemiparesis which mostly is preceded by herpes zoster ophthalmicus. Rarely varicella zoster vasculopathy presents as cauda equine syndrome or arterial dissection. Several school of thoughts believe arterial dissection is a complication from inflammation of vessel wall after varicella zoster infection which weakens the integrity of vessel wall and predisposes to aneurysm and finally rupture leading to catastrophic events like intracranial hemorrhage or subarachnoid hemorrhage [4-6]. There is no definite time period from the presentation of rash or herpes zoster and its complications, few case reports mention the simultaneous appearance of neurological symptoms with rash especially eye symptoms like vision loss due to central retinal artery occlusion or acute retinal necrosis. Other cases mentioned in literature appear as complication of remote infection which gets activated based on the immune status of the patient and can extend from a short duration of 5 months to couple of years. This is proved by the presence of varicella zoster virus antibody either IgG or M even after months of infection whereas the virus is cleared up from cerebrospinal fluid and serum of patient [7,8-11].

Varicella zoster virus vasculopathy can complicate varicella zoster or varicella in children and can significantly increase morbidity and mortality rate in affected individuals. Timely diagnosis and immediate treatment (especially the retinal symptoms) can lead to affective treatment of varicella zoster virus and related vasculopathic complications [12-16]. Certain salient features of this disease can support diagnosis and start empiric treatment while awaiting results of confirmatory tests which can take more than two weeks to be reported. These salient features are multifocal deep infarcts present at grey-white junction and mostly multifocal distribution as an embolic pattern of stroke. Most common vessels involved are small and large arteries followed by small sized arteries and finally long arteries getting involved [3,4]. Commonly more severe disease is noticed in immune - compromised patients like human immunodeficiency virus infected patients and other medication related [1,3]. Usually immunocompromised patients (HIV) have more multifocal presentation as compared to unifocal involvement which is more common presentation in immunocompetent patients. Eyes symptoms are more common in immunosuppressed patients and if not treated within the window period patient might suffer from complete blindness or significant vision loss [1,3-5,16]. Diagnosis of this treatable cause of stroke is often is missed due to one third patients present without skin rash, one third have normal cerebrospinal fluid (CSF) findings and an average 4.2 months delay from zoster to neurological signs and symptoms is noticed and varicella zoster virus DNA is negative in CSF at time of presentation. Various diagnostic tests can be obtained in order to diagnose Varicella zoster vasculopathy. CNS imaging like MRI or cerebral angiography can be obtained but approximately one third of the cases have normal imaging and those with positive results can be easily confused with other diseases that can have similar findings on brain imaging like brain metastasis, embolic disease etc. Clinical diagnosis should be suspected in patients with recent zoster or patients presenting with TIA or stroke evident clinically or on magnetic resonance imaging (MRI) of brain depicted by diffuse small infarcts at the junction of grey and white matter or in patients with above mention clinical symptoms and presence of monocytes pleocytosis and few red blood cells in CSF [4,11,19]. Though none of the above mentioned findings confirm the diagnosis but they indeed support the diagnosis and are one of the few clinical indicators based on which empiric treatment can be started. ELISA studies show oligoclonal bands in CSF of patients with varicella zoster virus vasculopathy is directed against causative virus and promising results helps in identifying varicella zoster as the cause of CNS symptoms. Immunoassay hold promise in confirming the specific oligoclonal bands in inflammatory CNS disease in which relevant antigen is unknown. But it is a long tedious assay as it takes more than 10 days to be reported as positive. ELISA of sera is a non specific test as studies have shown varicella zoster virus (VZV) IgG positive results when sera was negative in patients with chronic infection [8,9].

Varicella zoster virus related vasculopathy is the most treatable cause of CNS symptoms like stroke and other neurological deficits and acyclovir, an acyclic analogue of guanosine and is a selective inhibitor of VZV replication, is the most commonly studied treatment modality for varicella and other alphaviruses. Acyclovir has been proven to decrease duration of varicella zoster, early healing of lesions, reduce appearance of newer lesions and decrease severity of postherpetic neuralgia though studies mention questionable effect of antivirals on duration of postherpetic neuralgia and protection from vasculopathy and other related CNS complications [14,15,17]. Though other forms of tyrosine kinase inhibitors are present but limited trials have been conducted on the newer forms as varicella zoster vasculopathy is more common in pediatric population and other forms like valacyclovir are not available in liquid formulary hence cannot be easily administered

to younger patients [14]. Based on large available clinical trials both in adult and pediatric population, acyclovir is still considered as the drug of choice for varicella zoster and its related complications. Even in immunocompromised patient especially HIV patients, study trials have proven valacyclovir and acyclovir to be equally efficacious in healing of zoster related rash but none of these trials mention the role of treatment in preventing vasculopathy and CNS complications after varicella zoster infection [13,14,18]. Based on the large clinical trials and equivocal efficacy of acyclovir and its newer forms, better first hand clinical experience with acyclovir and easy formulation for all age groups acyclovir is still the drug of choice though mode of administration depends on severity of immunocompromised state of patient that is intravenous administration in patients with severe immunodeficiency whereas oral form can be used in patients with mild immunodeficiency [7,9,14]. As compared to herpes simplex virus no resistance to acyclovir is mentioned in literature so far and significant results have been obtained with above mentioned treatment strategies [17]. Where most of the symptoms of VZV vasculopathy respond to above mentioned treatment, visual symptoms or retinal involvement secondary to varicella zoster has the highest number of treatment failures as a result of which permanent vision loss is the most common residual of this disease [16]. Various studies mention lower number of patients with permanent damage or loss of vision, higher number of early responders and successful treatment with targeted approach that is intravitreal ganciclovir and systemic therapy as compared to systemic therapy alone. Some case reports mention the use of foscarnet with or without intravitreal ganciclovir as an alternative treatment modality for patients with retinal involvement with doubtful benefits in comparison to use of systemic and intravitreal tyrosine kinase inhibitors in a targeted manner [16]. Role of other medications like steroids is doubtful in immunocompromised patients and so far not recommended to be used even in adjunct with antiviral therapy. Only use of steroids so far validated is in cases of severe vessel wall inflammation which can predispose to thrombosis and segmental wall weakness leading to ectasia and aneurysm formation and thereby higher chances to stroke or intracranial hemorrhage [14-16]. But these trails mention to limit the use of steroids to less than 7 days as steroids carry risk of increase viral replication and persistence of chronic infection hence higher chances of developing vasculopathies in future.

Role of VZV vaccination in preventing varicella zoster related vasculopathy and CNS symptoms has not been studied so far but vaccination has been proven efficacious in decreasing the number of patients developing zoster or postherpete neuralgia [14]. Chemical prophylaxis in terms of long term use of acyclovir in immunocompromised patients in order to prevent recurrent VZV reactivation has not been approved by CDC so far. Hence use of acyclovir or valacyclovir in transplant or HIV patients is individually based whereas some authors do mention the efficacy of using 3 months prophylaxis in transplant patients especially the stem cell recipients on high dose immunosuppression and have higher chances to develop graft versus host disease (GVHD) [11-15].

Conclusion

Though varicella zoster vasculopathy is a treatable cause of stroke and other CNS manifestations but diagnosis is usually missed due to inconsistent findings on various test and long wait period in getting confirmatory test (CSF serology IgG/IgM antibody positive with VZV DNA positive or negative) results. This article highlights the various clinical findings and other indicators on ancillary tests which suggest VZV as a diagnosis and based on above empiric treatment should be started without waiting for positive serology to confirm diagnosis of VZV vasculopathy as delay in initiating treatment can increase mortality rate by 40-50% and also add to morbidities and poor quality of life after recovery from infection with permanent residual defects especially retinal damage/impaired visual fields [19].

References

1. Cohen JI, Brunell PA, Straus SE & Krause PR. Recent advances in varicella zoster infection. *Ann Intern Med*. 1999;130(11):922-932.
2. Gilden DH, Mahalingam R, Cohrs RJ, Kleinschmidt-DeMasters BK & Forghani B. The protean manifestations of varicella-zoster virus vasculopathy. *J Neurovirol.* 2002;8(suppl 2):75-79.
3. Nagel Maria A & Gilden Donald H. The protean manifestations of varicella-zoster virus vasculopathy. *CCJM.* 2007;74(7):489-494.
4. Harnisch JP. Zoster in the elderly: clinical, immunologic and therapeutic considerations. *J Am Geriatr Soc*. 1984;32(11):789-793.
5. Gilden DH, Cohrs RJ & Mahalingam R. Clinical and molecular pathogenesis of varicella virus infection. *Viral Immunol*. 2003;16:243-258.
6. Leppard B & Naburi AE. Herpes zoster: an early manifestation of HIV infection. *African Health.* 1998; 21(1):5-6.
7. Kakourou T, Theodoridou M, Mostrou G, Syriopoulou V, Papadogeorgaki H & Constantopoulos A. Herpes zoster in children. *J Am Acad Dermatol.* 1998;39(2 Pt 1):207-210.
8. Gold Eli. Serologic and virus-isolation studies of patients with varicella or herpes-zoster infection. *N Engl J Med*. 1966;274:181-185.
9. Head H, Campbell AW & Kennedy PG. The pathology of herpes zoster and its bearing on sensory localisation. *Rev Med Virol.* 1997;7(3):131-143
10. Huff JC. Antiviral treatment in chickenpox and herpes zoster. *J Am Acad Dermatol.* 1988;18(1 Pt 2):204-206.
11. Gilden D, Cohrs RJ, Mahalingam R, & Nagel MA. Varicella zoster virus vasculopathies: diverse clinical manifestations, laboratory features, pathogenesis, and treatment. *Lancet Neurol.* 2009;8(8):731-740.
12. Beutner KR, Friedman DJ, Forszpaniak C, Andersen PL & Wood MJ. Valaciclovir compared with acyclovir for improved therapy for herpes zoster in immunocompetent adults. *Antimicrob Agents Chemother.* 1995;39(7):1546-1553.
13. Tyring S, Barbarash RA, Nahlik JE, et al. Famciclovir for the treatment of acute herpes zoster: effects on acute disease and postherpetic neuralgia. A randomized, double-blind, placebo-controlled trial. Collaborative Famciclovir Herpes Zoster Study Group. *Ann Intern Med.* 1995;123(2):89-96.
14. John W. Gnann. Antiviral therapy for varicella zoster virus. Human Herpesviruses: Biology, treatment and prophylaxis, Chapter 65, NCBI Bookshelf, 2007.
15. Grose C. Pangaea and the Out-of-Africa Model of Varicella-Zoster Virus Evolution and Phylogeography. *J Virol.* 2012;86(18):9558-9565.
16. Gore DM, Gore SK & Visser L. Progressive outer retinal necrosis: outcomes in intravitreal era. *Arch Ophthalmol.* 2012;130(6):700-706.
17. Nau R, Lantsch M, Stiefel M, Polak T & Reiber H. Varicella zoster virus-associated focal vasculitis without herpes zoster: recovery after treatment with acyclovir. *Neurology.* 1998;51:914-915.
18. Toledo PV, Pellegrino LN & Cunha CA. Varicella-zoster virus encephalitis in an AIDS patient. *Braz J Infect Dis.* 2004; 8(3):255-258.
19. Saxena A, Khiangte B, Tiewsoh I & Jajoo UN. Herpes zoster encephalitis presenting as multiple cerebral hemorrhages - a rare presentation: a case report. *J Med Case Rep.* 2013;17:155.