

Wireless Capsule Endoscopy Detects Meckel's Diverticulum in an Adult: A Case Report

This article was published in the following Scient Open Access Journal:

Journal of General and Emergency Medicine

Received : May 02, 2017; Accepted May 22, 2017; Published May 29, 2017

Petkov A, Takorov I, Lukanova C, Mihaylov V*,
Katzarov K and Vladov N

Military Medical Academy - Sofia, Bulgaria

Abstract

Background: Meckel's diverticulum (MD) is the most common congenital anomaly of the gastrointestinal (GI) tract affecting approximately 2% of the population. A Meckel's diverticulum is a pouch on the wall of the lower part of the ileum. The diverticulum may contain tissue similar to that of the stomach or pancreas.

Case Report: The diagnosis of symptomatic MD is often difficult to make. We report on a 47-year-old male patient with recurrent obscure overt gastrointestinal bleeding (OGIB). He was referred after two episodes of melena and normal upper endoscopy. The lower endoscopy revealed blood coming from the proximal part of the small intestine. CT and angiography were performed as well but with negative results.

Meckel's diverticulum identification was achieved by wireless capsule endoscopy (WCE).

Conclusion: WCE is a helpful test to look for obscure GI bleeding in children and adults. It can be a helpful tool to diagnose MD especially if performed during or soon after active bleeding.

Keywords: Meckel's diverticulum; Obscure gastrointestinal bleeding; Wireless capsule endoscopy

Introduction

A Meckel's diverticulum (MD) is a vestigial remnant of the omphalomesenteric (vitellointestinal) duct. As a congenital anomaly, it is a true diverticulum that includes all three layers of the small intestine. Generally, a Meckel's diverticulum ranges from 1 to 12 cm in length and is found 45-90 cm proximal to the ileocecal valve. It frequently contains heterotopic tissue; when it does, gastric mucosa accounts for approximately 50%.

Pluripotential cells line the omphalomesenteric duct; thus, gastric, colonic, duodenal, and pancreatic mucosa may be present. The diverticulum may or may not be attached to the umbilicus with a fibrous cord. Autopsy records show that Meckel diverticulum occurs in about 2% of the general population. The male-to-female ratio is 3:1 for patients with symptomatic diverticula, but it is 1:1 for patients with asymptomatic diverticula [1].

We report on a 47-year-old male patient who had recurrent severe OGIB in a period of 7-10 days. He had a normal upper endoscopy. The lower endoscopy manifested blood from the proximal small intestine. An angiography and a CT were negative as well. MD identification was achieved by wireless capsule endoscopy (WCE).

Case Report

A 47-year-old male patient referred for investigation of obscure overt recurrent GI bleeding. He had 2 episodes of painless large amounts of melena for a period of 7-10 days associated with drop of hemoglobin to 11g/dl and to 6.6 g/dl after the second episode, blood transfusions were administered. He underwent extensive evaluation.

Upper and lower endoscopies were used to investigate the source of bleeding. The first upper and lower endoscopies were negative. After the second and more profuse bleeding a few days later a second look upper and lower endoscopy were performed.

*Corresponding Author: Mihaylov V, Military
Medical Academy - Sofia, Bulgaria, Email:
dr.mihaylov@gmail.com

Colonoscopy showed blood from the upper part of the small intestine. A CT and an angiography were negative. After his second OGIB he was referred for a WCE (Pillcam SB 3). The WCE revealed a Meckel's diverticulum in the distal part of the ileum with inflammatory changes (hyperemia) affecting the nearby area (Figures 1, 2 and 3) and a small insignificant angioectasia. The patient was referred for laparoscopic surgery. A 12 cm Meckel's diverticulum was found at approximately 100 cm above

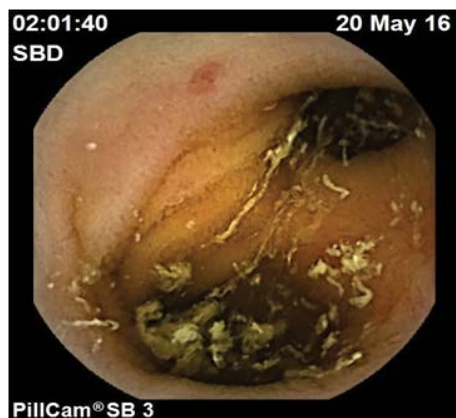

Figure 1: Wireless capsule endoscopy (WCE) images of Meckel's diverticulum.

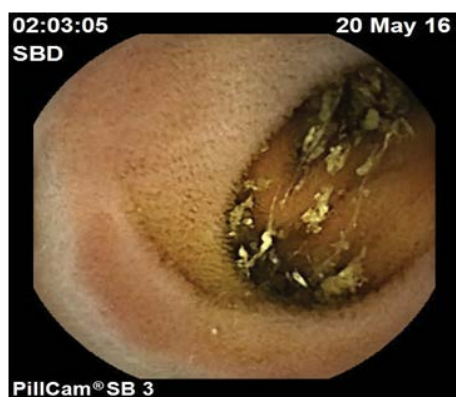

Figure 2: Wireless capsule endoscopy (WCE) images of Meckel's diverticulum.

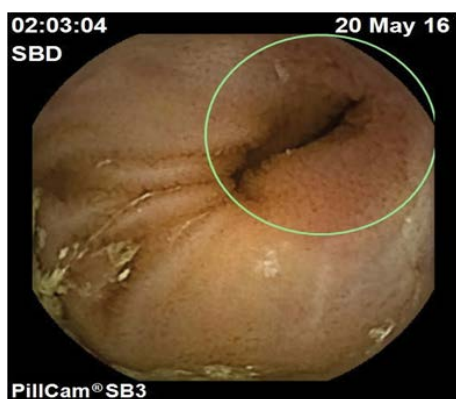


Figure 3: Wireless capsule endoscopy (WCE) images of Meckel's diverticulum.

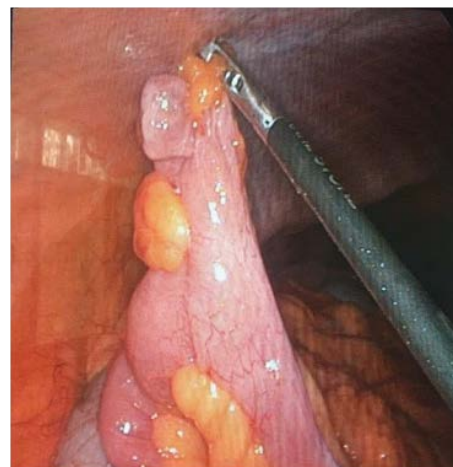

Figure 4: Laparoscopic image of Meckel's diverticulum.

the IC valve (Figure 4). A partial resection of the small bowel with termino-terminal anastomosis was performed. Histopathology confirmed the finding but no ectopic gastric mucosa was found.

The clinical course of the patient was uneventful and he was discharged on the 4-th postoperative day, no adverse events occurred. During the 8 months of follow up, he remained well without further bleeding episodes.

Discussion

Patients with upper GI bleeding often present with hematemesis or melena. The test used most often to diagnose the cause of GI bleeding is upper GI endoscopy. Colonoscopy is the test of choice in patients with rectal bleeding. Our patient suffered from melena, but unfortunately upper and lower endoscopy failed to detect the bleeding site. A lesion in the small bowel was suspected causing bleeding and MD was considered.

MD is the most common congenital anomaly of the GI tract. Although most cases are described in children and are discovered incidentally during laparotomy, it affects adults as well and manifests with GI bleeding, intussusception, perforation and obstruction, all of which require medical care.

MD is difficult to diagnose despite availability of modern imaging techniques. In most cases ^{99m}Tc -pertechnetate imaging is a diagnostic procedure that shows ectopic gastric mucosa, which is typical for symptomatic MD [2]. Gastric mucosa is the most common heterotopic tissue found in MD (>50%) followed by pancreatic tissue (5%) [3,4]. In a recent study heterotopic gastric tissue was found in 68.3% of patients with MD [5]. The highly acidic secretions of gastric tissue can cause ulcerations that often lead to GI bleeding [6,7].

Upper and lower endoscopy in our case failed to detect the source of bleeding. A CT of the abdomen and an angiography did not deliver any positive results as well. Success in establishing a diagnosis was obtained by WCE.

Menezes et al. in 2008 reported that MD has various presentations and can be easily misdiagnosed [8]. The records of 71 patients with a diagnosis of MD were retrospectively reviewed. In 8 patients MD was an incidental finding at laparotomy, 35

patients (55.5%) presented with episodes of rectal bleeding, 10 patients (15.8%) had clinical features of peritonitis, 9 patients (14.2%) were diagnosed with intestinal obstruction, and 9 patients (14.2%) had a patent vitello-intestinal duct that presented with umbilical discharge. Hemorrhage, intestinal obstruction and diverticulitis are the most frequent complications in adults.

Meticulous examination with enteroclysis has been reported to be more sensitive [6]. CT angiography is not always diagnostic because the arterial supply of the intestine may not be impaired and it can only detect bleeding of at least 1-2 ml/min [9].

One of the newer technologies that expands the diagnostic capabilities of pathology in the small intestine is WCE.

Handful case reports have been published detecting MD using capsule endoscopy. Xinias et al. and Ayesh K. et al. reported an 8-year-old boy and a 7-year-old boy, who presented with GI bleeding due to MD. Upper and lower endoscopy in addition to Meckel scan failed to diagnose the source of bleeding [5,10].

Conclusion

WCE is a helpful test to look for obscure GI bleeding in children and adults. It can be a helpful tool to diagnose MD especially if performed during or soon after active bleeding. More controlled studies are needed to delineate the role of WCE in diagnosing symptomatic MD.

References

1. Nafisa K Kuwajerwala, John Geibel. Meckel Diverticulum. Medscape, Updated: Apr 02, 2015.
2. Martin JP, Connor PD, Charles K. Meckel's diverticulum. *Am Fam Physician*. 2000;61(4):1037-1042.
3. Cullen JJ, Kelly KA, Moir CR, Hodge DO, Zinsmeister AR, Melton LJ, 3rd. Surgical management of Meckel's diverticulum. An epidemiologic, population-based study. *Ann Surg*. 1994;220(4):564-569.
4. Turgeon DK, Barnett JL. Meckel's diverticulum. *Am J Gastroenterol*. 1990;85:777-781.
5. Xinias I, Mavroudi A, Fotoulaki M, Tsikopoulos G, Kalampakas A, Imvrios G. Wireless Capsule Endoscopy Detects Meckel's Diverticulum in a Child with Unexplained Intestinal Blood Loss. *Case Rep Gastroenterol*. 2012;6(3):650-659.
6. Maglinte DD, Elmore MF, Isenberg M, Dolan PA. Meckel diverticulum: radiologic demonstration by enteroclysis. *Am J Roentgenol*. 1980;134:925-932.
7. Williams RS. Management of Meckel's diverticulum. *Br J Surg*. 1981;68:477-480.
8. Menezes M, Tareen F, Saeed A, Khan N, Puri P. Symptomatic Meckel's diverticulum in children: a 16-year review. *Pediatr Surg Int*. 2008;24(5):575-577.
9. Laing CJ, Tobias T, Rosenblum DI, Banker WL, Tseng L, Tamarkin SW. Acute Gastrointestinal Bleeding: Emerging Role of Multidetector CT Angiography and Review of Current Imaging Techniques. *Radiographics*. 2007;27(4):1055-1070.
10. Ayesh K, Dweikat IJ, Ciecierrega T, Sultan M. Capsule Endoscopy detects Meckel's Diverticulum in a Child with Recurrent Gastrointestinal Bleeding: Case report and Review of the Literature. *J Gastric Disord Ther*. 2016