

## Congenital Anhidrotic Ectodermal Dysplasia: A Rare Neonatal Presentation

This article was published in the following Scient Open Access Journal:

Journal of Integrative Pediatric Healthcare

Received August 05, 2017; Accepted August 18, 2017; Published August 25, 2017

Geetanjali Srivastava<sup>1</sup>, Harshal Khade<sup>2</sup>, Uma Raju<sup>3\*</sup>, Shashank Panwar<sup>4</sup>

<sup>1</sup>Nice Hospital, India.

<sup>2</sup>Nice Hospital for Newborns, Women & Children, India.

<sup>3</sup>Consultant Neonatologist, India.

<sup>4</sup>Nice Hospital for Newborns, Women & Children, India.

### Abstract

Anhidrotic Ectodermal Dysplasia is a rare genetic disorder of structures derived from embryonic ectoderm primarily affecting skin, sweat glands and dentition. Clinical features include hyperthermia, dry scaly skin, scanty hypopigmented hairs, hypohidrosis and adontia which usually manifest beyond infancy. It carries a male preponderance. Features are rarely evident in neonatal period and occur more commonly in older children. Diagnosis is based on clinical presentation supported by demonstration of reduced sweat glands by histopathology studies of skin biopsy and the absence/mutation of ectodysplacin gene on genetic studies. There is no definitive treatment but conservative measures viz prevention of hyperthermia, psychological support, artificial dentures enable an improved quality of life. We report a rare case of anhidrotic ectodermal dysplasia who presented on 5<sup>th</sup> day of life with hyperthermia and seizures. The baby exhibited several dysmorphic features viz absent eyebrows, hypopigmented hair, dry skin, premature aged appearance and periorbital hyperpigmentation. Skin biopsy obtained from right hypothenar eminence revealed an absence of sweat glands and orthokeratosis of epidermis. There was no haematological evidence of infection and EEG showed diffuse bilateral hemispherical slowing. His maternal uncle aged 8 years had similar dysmorphic features, adontia and frequent episodes of hyperthermia. Temperature control, management of seizures, skin emollients and supportive care were provided with gratifying results. Ectodermal dysplasia should be considered in a newborn presenting with unexplained hyperpyrexia and seizures.

**Purpose:** An unusual presentation i.e. severe hyperthermia and seizures in the absence of infection and pathognomic dysmorphic features which manifested in the early neonatal period – an exceedingly rare occurrence. This case demonstrates the need to have a high index of suspicion when babies present with hyperthermia in the early neonatal period without other evidence of sepsis.

**Keywords:** Ectodermal dysplasia , Adontia , Anhidrosis , Ectodysplacin

### Introduction

Ectodermal dysplasia is a congenital heterogenous group of disorders primarily involving tissues derived from embryonic ectoderm like skin, hair, nails, eccrine glands and teeth [1]. This rare disease occurs in approximately 1 per 1,00,000 live births [2]. Depending upon the present number of sweat glands and mode of inheritance, ectodermal dysplasia is classified into two categories- hypohidrotic or anhidrotic ectodermal dysplasia(X-linked) and hydrotic ectodermal dysplasia(autosomal dominant) [3,4]. The triad of nail dystrophy (onchodysplasia), alopecia or hypotrichosis (scanty, fine light hair on the scalp and eyebrows) and palmoplantar hyperkeratosis is usually accompanied by a lack of sweat glands (hypohidrosis) and a partial or complete absence of primary and/or permanent dentition [5].

Hypohidrotic or Anhidrotic type of ectodermal dysplasia manifests as hypotrichosis, hypodontia, inability to sweat, hyperthermia and cranio facial abnormalities. These changes are rarely apparent in the newborn but are usually detected in late infancy [6,7].

In this case report we describe the disease in a newborn presenting on 5<sup>th</sup> day of life with hyperthermia and seizures, having cranio-facial features characteristic of ectodermal dysplasia. Diagnosis was made on dermal punch biopsy which showed absence of pilosebaceous and sweat glands in epidermal and dermal layers. This case report describes the unusual presentation of anhidrotic ectodermal dysplasia early

\*Corresponding Author: Uma Raju, Consultant Neonatologist, Nice Hospital, Hyderabad, Telangana, India, Tel: 91-7093150968, Email: [majenumaraju@gmail.com](mailto:majenumaraju@gmail.com)

in the neonatal period with life threatening features of severe hyperpyrexia and status epilepticus.

### Case Report

A term, male neonate with birth weight of 2500 gm was born to a primigravida aged 20 years out of a second degree consanguineous marriage by normal vaginal delivery at a peripheral rural birth centre. There were no known antenatal, natal or postnatal adverse events. The baby developed fever on 2<sup>nd</sup> day of life which progressively increased in spite of hydrotherapy. The neonate developed seizures on the 5<sup>th</sup> day of life when he was hospitalized.

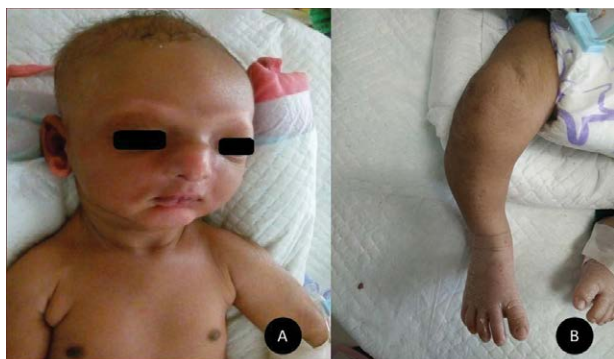At admission he was severely hyperthermic (40.2°C). The neonate was suffering from seizures in the form of cyclical movements and staring look since 3 hours. He was provided parenteral phenobarbitone in maximum doses followed by levetiracetam to achieve seizure control. The hyperpyrexia was controlled with rectal paracetamol and hydrotherapy.

Detailed examination revealed an irritable neonate with multiple dysmorphic features viz scanty and light coloured scalp hairs with sparse eyebrows, hyperpigmentation around eyes, skin peeling around lower limbs, thin depressed nasal bridge, prominent forehead, malar hypoplasia and broad rib cage giving appearance of widely spaced nipple (Figure 1). Systemic examination revealed no abnormality.

There was a family history of similar features in a third degree male relative who is 8 years of age and had history of heat intolerance, edentulous jaws and characteristic facial features. He also had dryness of skin and palmar hyperkeratosis (Figure 2).

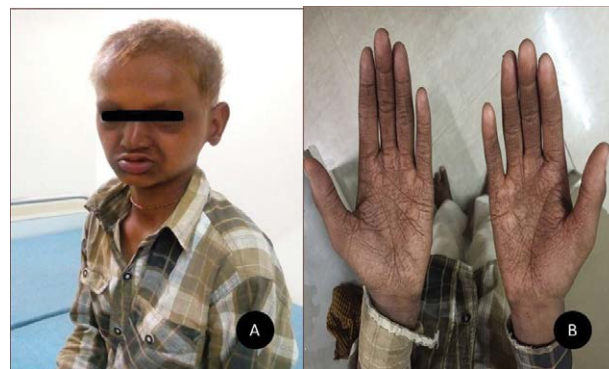In view of the clinical presentation dysmorphic features pathognomic of anhidrotic ectodermal dysplasia and family history of similar disease, punch biopsy skin specimen was obtained from right hypothenar eminence to establish a histopathological diagnosis.

Skin biopsy report revealed a broad band of orthokeratosis with hypergranulosis of epidermis, loosely packed collagen with scattered nuclei of fibroblasts and many thin walled vessels in the dermis. Most importantly the absence of pilosebaceous units, hair



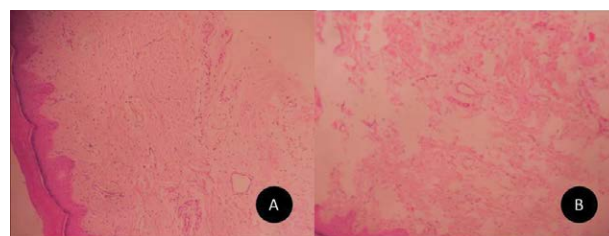
**Figure 1. Clinical Photograph of Neonate with Anhidrotic Ectodermal Dysplasia**

[A] Facial photograph of baby showing scanty and light coloured scalp hairs with sparse eyebrows, hyperpigmentation around eyes, thin depressed nasal bridge, prominent forehead, malar hypoplasia, broad rib cage giving appearance of widely spaced nipple.  
[B] Photograph of lower limbs showing dryness & scaling of skin.



**Figure 2. Clinical Photograph of 8 year old Cousin Suffering from Hypohidrotic Ectodermal Dysplasia**

[A] Hyperpigmentation around eyes, prominent forehead, malar hypoplasia, sparse hypopigmented hairs, absent teeth, edentulous jaws.  
[B] Dryness and scaling of skin, palmar hyperkeratosis.



**Figure 3. Histopathological Examination of Skin Biopsy**

[A] Broad band of orthokeratosis with hypergranulosis. Loosely packed collagen with scattered nuclei of fibroblasts and many thin walled vessels in the dermis.  
[B] Absence of pilosebaceous units, hair follicles, sweat glands and eccrine gland.

follicles, sweat glands and eccrine glands in the multiple serial sections have been studied. The biopsy findings were suggestive of ectodermal dysplasia (Figure 3).

The other detailed investigations revealed a normal total and differential leucocyte counts, normal serum electrolyte panel, negative septic screen, normal kidney functions, calcium and blood gas analysis. Cranial and abdominal ultrasonogram and 2D Echo did not reveal any abnormality. EEG record revealed bilateral diffuse bihemispherical slowing.

### Discussion

Anhidrotic ectodermal dysplasia, also known as Christ Siemens Tauraine syndrome, has a rare occurrence [6]. The disease has an incidence of 1 per 100000 male births with X linked recessive mode of inheritance. It generally manifests in early childhood and sometimes in late infancy. The gene is localised to Xq11.21.1 locus. The most serious problem is absent eccrine sweat glands causing diminution of sweating response leading to marked heat intolerance and episodes of hyperthermia [8]. The craniofacial characteristics include frontal bossing, mid face hypoplasia, flattened nasal bridge, thick upper lips, scanty and light coloured scalp hair and eyebrows. These features rarely manifest in the newborn [9]. The index case manifests all of these features and presented with hyperthermia and skin peeling in addition which is an exceedingly uncommon presentation. It thus suggested a phenotypically severe manifestation of the condition.

Mode of inheritance includes X-linked recessive (95%), autosomal dominant or autosomal recessive (5%) forms. Ectodermal dysplasia involves mutations in genes encoding several proteins having roles in the ectodysplasin signal transduction pathway. Mutations in the EDA gene, which encodes the ectodysplasin ligand that initiates signalling through this pathway, cause the X-linked recessive form. Mutations in the genes encoding the EDA receptor and the adaptor protein that associates with the EDA receptor's death domain result in autosomal dominant and autosomal recessive forms, respectively [10-12].

Congenital absence of teeth and teeth malformation leading to underdevelopment of alveolar ridges presents with edentulous jaws in rare instances [13]. Our patient presented on the 5<sup>th</sup> day of life with hyperthermia and seizures (which could be attributed to temperature instability). Facial features included sparse and light coloured scalp and eyebrow hairs, prominent forehead, depressed nasal bridge and dark pigmentation around eyes thus giving a premature aged appearance. The baby had skin peeling around lower limbs bilaterally. A third degree male relative aged 8 years was similarly afflicted with pathognomic facial features, adontia and heat intolerance.

Hydrotic ectodermal dysplasia, also known as Clouston syndrome, has characteristic abnormality of skin, hair and nails. It has autosomal dominant pattern of inheritance with normal sweat glands and teeth anatomy [14]. Facial features are similar to hypohidrotic variety except for hyperpigmentation of skin around knees, elbow and knuckles with palmo plantar keratoderma which were not present in our patient [13,14]. A differential diagnosis of Aplasia cutis congenital, Focal dermal hypoplasia syndrome, Incontinentia pigmenti, Pachyonachia congenital were made. Congenital alopecia cutis manifests with cicatricial alopecia and histopathologically there is focal absence of epidermis, as opposed to ectodermal dysplasia which involves the dermis. Focal dermal hypoplasia syndrome involves presence of aplastic and hypoplastic areas manifesting as yellow pink bumps over skin which was not present in our patient. Neonatal presentation of Incontinentia pigmenti involves vesicular and verrucose skin lesions with hyperpigmentation (Blaschko lines) over extremities, trunk, head and neck. The disorder also involves teeth malformation. These dermal markers were not seen in our patient.

Diagnostic investigations include palmar skin biopsy demonstrating absent or hypoplastic eccrine sweat glands, pilocarpine iontophoresis and karyotype analysis. In our patient palmar skin biopsy revealed complete absence of pilosebaceous and eccrine sweat glands clinching the diagnosis of anhidrotic ectodermal dysplasia and suggestive of severe manifestation of the disease.

Genetic studies reveal X linked inheritance manifesting mainly in the male with gene locus being Xq11-21.1 and gene affected being EDA gene [15]. These studies where available would aid in further substantiating the diagnosis.

Management includes parental education and counselling about and protection from overheating. Conservative measures like use of artificial tear drops for defective lacrimation, use of nasal saline drops and skin emollients are employed. Regular dental evaluation should begin early in life thus facilitating use of

artificial dentures in order to promote good nutrition, articulation and facial appearance [16-18]. In the index case, parents have been cautioned to prevent and treat hyperthermia. Skin emollient application and artificial tears usage have been advised. Also they have been cautioned about the impending adontia and the need for artificial dentures in later years.

There are case reports of diagnosing ectodermal dysplasia based on absent teeth and teeth malformations in early childhood. However, its presentation in early newborn period with hyperpyrexia and seizures is exceedingly rare.

## Conclusion

Anhidrotic ectodermal dysplasia is a rare genetic disorder usually presenting after infancy and in early childhood. The disease should be considered in a baby presenting with recurrent episodes of unexplained hyperthermia, hypotrichosis, hypodontia, inability to sweat and cranio facial abnormalities. A positive family history is contributory. Presentation in the neonatal period is rare. However diagnosing it in the neonate prevents majority of complications, prepares the parents, enables early genetic counselling and hence improves overall outcome. Neonatal presentation of this condition is a rarity. Our case was thus unusual in its early presentation in neonatal period suggestive of a severe disease. To the best of our knowledge no case report of this disease presenting as severe hyperthermia and status epilepticus in the early newborn period is known.

## References

- Dhanrajani PJ, Jiffy AO. Management of Ectodermal Dysplasia: A Literature Review. *Dent Update*. 1998;25(2):73-5.
- Kupietzky K, Milton H. Hypohidrotic ectodermal dysplasia: Prosthetic management of hypohidrotic ectodermal dysplasia. *Quintessence Int*. 1995;26:285-291.
- Vieira KA, Teixeira MS, Guirado CG, et al. Prosthodontic treatment of hypohidrotic ectodermal dysplasia with complete anodontia: case report. *Quintessence Int*. 2007;38:75-80.
- Abadi B, Herren C. Clinical treatment of ectodermal dysplasia: a case report. *Quintessence Int*. 2001. 32:743-745.
- Yavuz I, Ulku SZ, Unlu G, et al. Ectodermal dysplasia: clinical diagnosis. *Int Dent Med Disorders*. 2008;1(1):1-10.
- Lamartine J, Munhoz Essenfelder G, Kibar Z, et al. Mutations in GJB6 cause hidrotic ectodermal dysplasia. *Nat Genet*. 2000;26:142-144.
- Bani M, Tezkirecioglu AM, Akal N, et al. Ectodermal Dysplasia with Anodontia: A Report of Two Cases. *Eur J Dent*. 2010;4(2):215-222.
- Richards W, Kaplan M. Anhidrotic ectodermal dysplasia: An unusual cause of hyperpyrexia in the newborn. *Am J Dis Child*. 1969;117(5):597-598.
- Reed WB, Lopez DA, Landing B. Clinical spectrum of anhidrotic ectodermal dysplasia. *Arch Dermatol*. 1970;102(2):134-143.
- Agarwal S, Gupta S. Hypohidrotic ectodermal dysplasia. *Indian Dermatol Online J*. 2012;3(2):125-127.
- Kere J, Srivastava AK, Montonen O, et al. X-linked anhidrotic (hypohidrotic) ectodermal dysplasia is caused by mutation in a novel transmembrane protein. *Nat Genetic*. 1996;13(4):409-416.
- Bal E, Baala L, Cluzeau C, et al. Autosomal dominant anhidrotic ectodermal dysplasias at the EDARADD locus. *Hum Mutat*. 2007;28(7):703-709.
- Crawford PJ, Aldred MJ, Clarke A, et al. Rapp-Hodgkin syndrome: An ectodermal dysplasia involving the teeth, hair, nails and palate. *Oral Surg Oral Med Oral Pathol*. 1989;67(1):50-62.
- Sharma J, Mamatha GP. Hereditary ectodermal dysplasia: Diagnostic

- dilemmas. *Rev Clin Pesq Odontol.* 2008;4(1):35-40.
15. Itthagaran A, King NM. Ectodermal Dysplasia: a review and case report. *Quintessence Int.* 1997;28(9):595-602.
16. Tarjan I, Gabris K, Rozsa N. Early prosthetic treatment of patients with ectodermal dysplasia: a clinical report. *J Prosthet Dent.* 2005;93(5):419-424.
17. Yavuz I, Kiralpve S, Baskan Z. Hypohyrotic Ectodermal Dysplasia: A Case Report. *Quintessence Int.* 2008;39(1):81-86.
18. Yildirim M, Oktay MF, Ozmen C, et al. Reveal by Biotechnological Equipment to the Bilateral Nonfunctional Submandibular Glands in Ectodermal Dysplasia. *Biotech & Biotechnol Equip.* 2008;22(4):1005-1007.